

Clinical and Systemic Effects of Periodontally Accelerated Osteogenic Orthodontics: A Pilot Study

Efectos Clínicos y Sistémicos de la Ortodoncia Osteogénica
Periodontalmente Acelerada: Un estudio Piloto

Juan Fernando Aristizabal^{*}; Wilhelm Bellaiza^{***}; Mario Alejandro Ortiz^{****} & Leonardo Franco^{**}

ARISTIZABAL, J. F.; BELLAIZA, W.; ORTIZ, M. A. & FRANCO, L. Clinical and systemic effects of periodontally accelerated osteogenic orthodontics: a pilot study. *Int. J. Odontostomat.*, 10(1):119-127, 2016.

ABSTRACT: The aim of this study was to describe periodontal effects and treatment time of Periodontally Accelerated Osteogenic Orthodontics (PAOO) and to determine if Deoxyypyridinoline could be used as a biochemical marker of bone turnover in patients undergoing PAOO. We compared 5 patients undergoing PAOO (5 males, mean age: 29.6±9.8 years) with 5 control patients undergoing self-ligating orthodontics (5 males, mean age: 28.5±6.3 years). All patients were evaluated using panoramic and lateral x-rays and CBCT and randomly selected in experimental and control groups. Both groups underwent self-ligating orthodontics using Damon Q braces. Only the experimental group underwent PAOO. The patients were evaluated periodontally at T1 (before surgery and orthodontic movement) and T2 (after orthodontic treatment). The total treatment time for the experimental group was 8.2±3.3 months and for the control group was 13.4±7.3 months. There were no differences between T2-T1 periodontal variables in either of the groups. Gingival recession was 0.49±0.26 mm at T1 and 0.42±0.3 mm at T2 in the experimental group. Gingival recession was 0.55±0.31 mm at T1 and 1.19±0.24 mm at T2 in the control group. Deoxyypyridinoline urine levels showed great variance between individuals and between groups. There is a reduction in treatment time for patients undergoing PAOO with DAMON Q braces. There is no difference in the periodontal condition between PAOO and conventional orthodontics.

KEY WORDS: periodontally accelerated osteogenic orthodontics (PAOO), self-ligating orthodontics, Wilckodontics, corticotomy, deoxyypyridinoline, regional acceleratory phenomenon (RAP).

INTRODUCTION

Current orthodontic practice has to face new challenges. First, an increasing number of adult patients are seeking orthodontic treatment (Mathews & Kokich, 1997). Adults have more specific objectives related to aesthetics, function and efficiency (Hassan *et al.*, 2010). Compared to children, they also have biological differences: cell response, collagen metabolism, hyalinization and periodontal tissues variations (Ong & Wang, 2002). Second, there is a constant demand for shorter treatments. Orthodontic treatment time ranges between 21–27 and 25–35 months for non-extraction and extraction therapies, respectively (Buschang *et al.*, 2012). The search for treatment efficiency has resulted in the development

of multiples strategies such as low friction and self-ligating braces, and alveolar corticotomies.

The development of corticotomy-assisted orthodontics opens a new opportunity for adult treatment. Although, “surgically facilitated orthodontic therapy” was proposed in the last century (Murphy *et al.*, 2012), Wilcko *et al.* (2001), integrated corticotomy with grafting, and proposed selective alveolar decortication in order to induce regional osteopenia and accelerate orthodontic tooth movement. Using Periodontally Accelerated Osteogenic Orthodontics (PAOO), Wilcko *et al.* (2003), reported a movement rate 3 to 4 times faster than conventional tooth movement.

^{*} Orthodontist. Associated professor and head, Department of Orthodontics, Universidad del Valle, Cali, Colombia.

^{**} Orthodontist, Private practice, Cali, Colombia.

^{***} Periodontist, Professor of Ortho-Perio Relationships, Department of Orthodontics, Universidad del Valle, Cali, Colombia.

^{****} Orthodontist. Master in Biomedical Sciences. Assistant Professor, Department of Morphology, Universidad del Valle, Private practice, Cali, Colombia.

The biological basis of PAOO is Regional Acceleratory Phenomenon (RAP), first described by Frost (1983), who related the severity of bone injury with intensity of bone healing. RAP is a temporary stage of soft and hard tissue remodeling in response to inflammatory signals (Weiss *et al.*, 2002), increasing osteoclast and osteoblast recruitment. RAP accelerates tissue metabolism and increases tissue reorganization (Hassan *et al.*). Therefore, RAP healing is a complex physiological process with dominating features involving accelerated bone turnover and decreases in regional bone densities (Wilcko *et al.*, 2001).

RAP induces regional osteopenia and accelerates tooth movement. Several histological evaluations in bio models have added more evidence of this effect (Cho *et al.*, 2007; Iino *et al.*, 2007; Wang & Yen, 2008). Corticotomy was found to increase catabolic activity around the tooth and the spongy bone, generating local osteopenia. Wang *et al.* (2009), also showed the reversibility of the process. Mueller *et al.* (1991), detected systemic effects of corticotomy in rat tibia; this opens the opportunity to evaluate bone remodeling associated with RAP using biochemical bone markers (Blumsohn & Eastell, 1997).

The aim of this study is to describe the effect in total treatment time and in periodontal tissues of Periodontally Accelerated Osteogenic Orthodontics (PAOO) and evaluate the effects of corticotomy in bone turnover through urinary Deoxypyridinoline levels.

MATERIAL AND METHOD

Patient selection. A group of 10 male patients, with ages ranging from 18 to 40, treated at the Orthodontics Department, University of Valle, were selected for this study. All Protocols were approved by the University Human Ethics Committee. Three months before, the patients were included in a strict periodontal protocol, based on plaque control and dental prophylaxis. Inclusion criteria included: class I and II malocclusion, mild crowding, periodontal health and 20 % plaque index. Exclusion criteria included: bone or metabolic disease, history of bone fractures 6 months before treatment, history of orthopedic or oral surgery 6 months before treatment and bisphosphonates therapy. For each patient, the diagnosis was based on standard orthodontic documentation with photographs, model cast, cephalogram, panoramic radiographies and periodontal chart. An additional CBCT was also taken (Fig. 1). The treatment plan for these patients included non-extraction comprehensive orthodontics using self-ligating braces (Damon TM). After a clear explanation of all of the risks and benefits of the treatment, all patients consented to this study.

Treatment . Patients were randomly divided into two groups: Periodontally Accelerated Osteogenic Orthodontics (PAOO) group (n= 5, mean age: 29.6±9.8 years) and Control Group (n= 5, mean age: 28.5±6.3 years). All patients underwent comprehensive

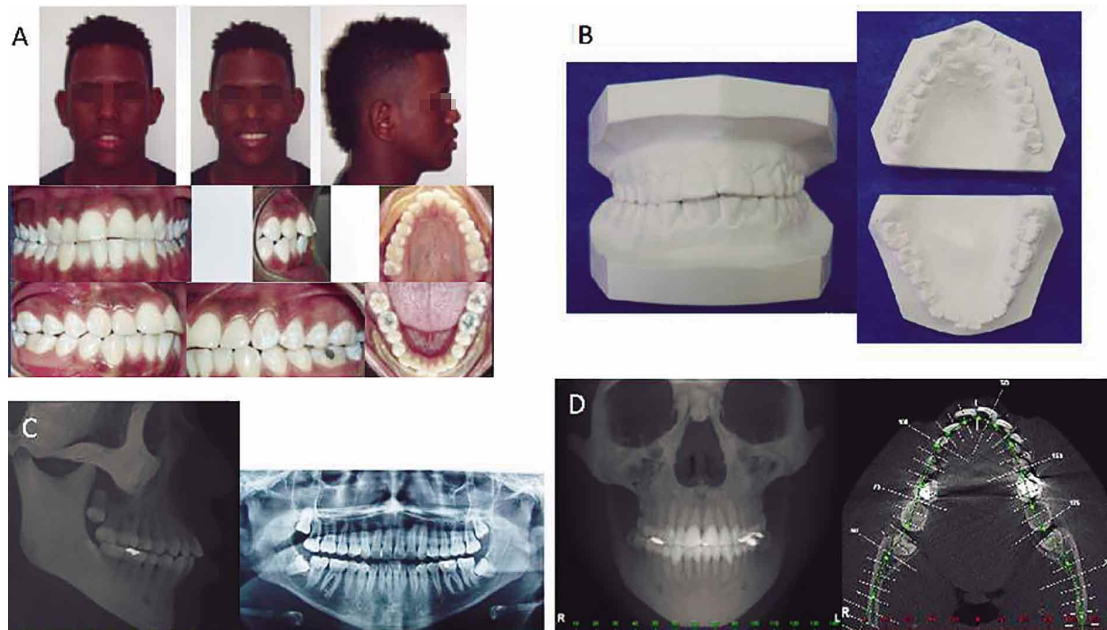


Fig. 1. Example of the standard orthodontic documentation with photographs, model cast, cephalogram, panoramic radiographies and CBCT.

orthodontic treatment using Damon Q self ligating braces. Patients in both groups were first treated using Unity 0.014 inch wire. Differences between the experimental and the control group were:

1) The experimental group underwent Periodontally Accelerated Osteogenic Orthodontics following Wilcko *et al.* (2001) protocol. Briefly, after brackets were cemented to the labial surfaces of the tooth, mucoperiosteal flaps were

raised in the vestibular surfaces in the lower and upper teeth beyond the apical zones, selective decortications were made and Bone Allograft (Puros™, Zimmer Dental) was placed in the areas that had undergone corticotomies. After 2 days, Unity 0.014 inch wire was used (Fig. 2).

2) All patients in the experimental group were evaluated every two weeks according to PAOO protocol.

All patients were under periodontal control during active orthodontics treatment and were Periodontally evaluated by the same individual at two different times: before surgery and orthodontic movement (T1) and after orthodontic treatment (T2). During evaluations, employing a constant pressure probe (Florida Probe Corporation) the following periodontal variables were considered: PD probing and Gingival Recession (Fig. 3).

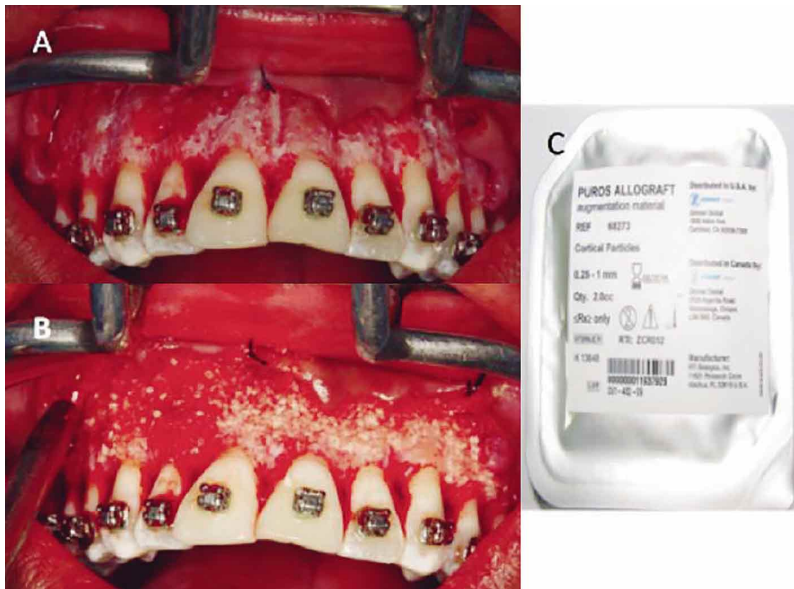

Fig. 2. Surgical procedure of the experimental group underwent Periodontally Accelerated Osteogenic Orthodontics. A) Mucoperiosteal flaps were raised in the buccal surfaces in the lower and upper teeth beyond the apical zones. B) Selective decortications were made and C) Bone Allograft (Puros™, Zimmer Dental) was placed in the areas that had undergone corticotomies.

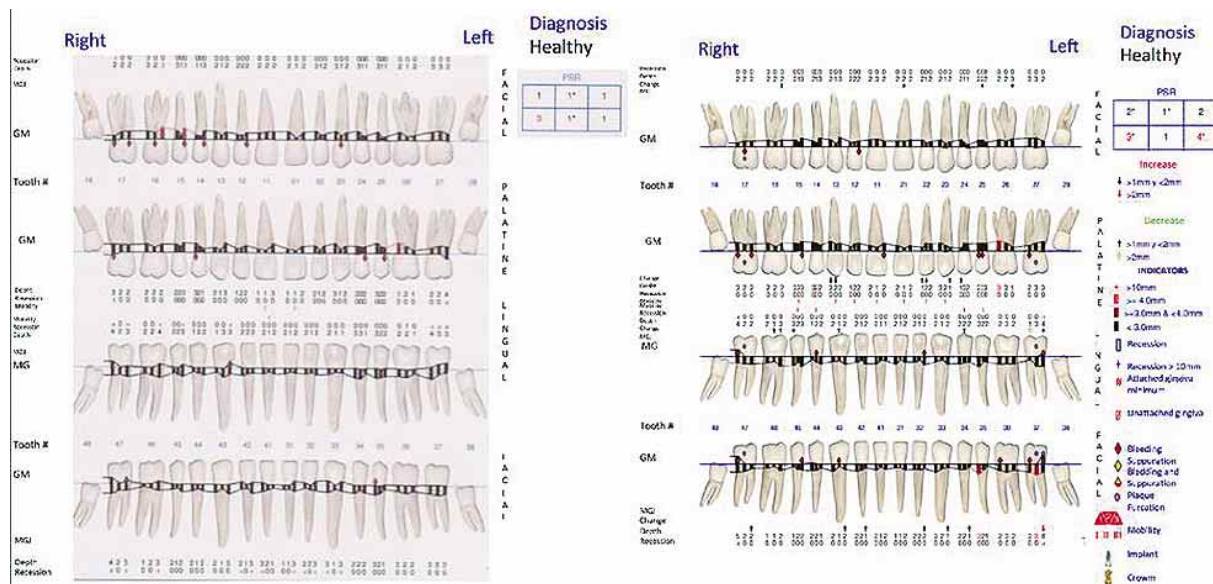


Fig. 3. Periodontal charts. Patients were under periodontal control during active orthodontics treatment and were Periodontally evaluated by the same individual at two different times: before surgery and orthodontic movement (T1) and after orthodontic treatment (T2).

Deoxyypyridinoline Evaluation. In order to evaluate bone turnover, as an indicator of RAP, deoxyypyridinoline (DPD) urine levels were measured through High-Performance Liquid Chromatography (HPLC) using spontaneous urine samples with 2 h between collection and processing of the sample. As DPD excretions follows circadian rhythm, urine samples were taken first in the morning.

In order to determine temporal changes in bone turnover during orthodontic treatment in both groups, DPD levels were evaluated at three different times:

| DEOXYPYRIDINOLINE (Pirilinks) | RESULTS | |
|-------------------------------|---------|----------|
| Deoxyypyridinoline | 114 | nmol |
| Creatinuria | 20.6 | mmol/L |
| Pirilink (DPD/Creatinuria) | 5.5 | nmol DPD |

| DEOXYPYRIDINOLINE (Pirilinks) | RESULTS | |
|-------------------------------|---------|----------|
| Deoxyypyridinoline | 160 | nmol |
| Creatinuria | 20.6 | mmol/L |
| Pirilink (DPD/Creatinuria) | 7.7 | nmol DPD |

Reference Values:
 Men: 2.3- 5.4 nmol DPD/mmol Creatinine
 Women: 3.0 - 7.4 nmol DPD/mmol Creatinine
 Prepubertal: 13.4 - 60.4 nmol DPD/mmol Creatinine
 Pubertal: 11.4 - 85.9 nmol DPD/mmol Creatinine
 Postpubertal: 3.9 - 24.6 nmol DPD/mmol Creatinine

Fig. 4. Deoxyypyridinoline (DPD) levels evaluation. T1 levels were used to determine the patients' base lines, T2 evaluated bone turnover after decortications and T3 evaluated the RAP therapeutic window.

before surgery and orthodontic movement (T1), 2 d after surgery (T2) and 6 months after surgery (T3). T1 levels were used to determine the patients' base lines, T2 evaluated bone turnover after decortications and T3 evaluated the RAP therapeutic window (Fig. 4).

RESULTS

A trial profile for the participating patients is shown in Table I. All patients completed the trial and received follow-up care. There was no statistical difference between mean ages in the 2 groups.

Table II shows total treatment time data. Total treatment time for the experimental group was 8.2±4.49 months and for the control group was 13.4±6.26 months. There was no statistical difference between the groups (p= 0.17).

The type of treatment showed no differences in periodontal initial (T1) and final (T2) conditions. Gingival Recession was 0.49±0.26 mm at T1 and 0.42±0.3 mm at T2 in experimental Group. Gingival Recession was 0.55±0.31 mm at T1 and 1.19±0.24 mm at T2 in control group (Table III).

Table I. Trial profile for the control and experimental group.

| PAOO Group | Control Group |
|----------------------------------|---|
| Received PAOO Intervention: n= 5 | Received Orthodontic Intervention: n= 5 |
| Mean age: 29.6±9.8 years | Mean age: 28.5±6.3 years |
| Followed-up: n= 5 | Followed-up: n= 5 |
| Completed Trial: n= 5 | Completed Trial: n= 5 |

Table II. Total treatment time for the control and experimental group.

| | Total Treatment Time | | |
|---------------|----------------------|------|---------|
| | Mean (SD) | SE | P value |
| PAOO Group | 8.2 (4.49) | 2.01 | 0.17 |
| Control Group | 13.4 (6.26) | 2.8 | --- |

Table III. Periodontal initial and final conditions in control and experimental group.

| | | Deep of Probing | | Marginal Recession | |
|---------------|----------------|-----------------|-------|--------------------|-------|
| | | Mean | SD | Mean | SD |
| Test Group | Baseline | 1.854 | 0.748 | 0.475 | 0.518 |
| | AfterTreatment | 1.531 | 0.736 | 0.471 | 0.599 |
| Control Group | Baseline | 1.766 | 0.808 | 0.551 | 0.563 |
| | AfterTreatment | 1.370 | 0.851 | 1.192 | 0.491 |

Urine Deoxypyridinoline levels showed great variance between individuals and between groups, so no conclusion could be made. However, urine

Deoxypyridinoline levels could be used as a bone turnover marker in some patients. DPD levels data are shown in Table IV.

Table IV. Evaluation of urine Deoxypyridinoline levels between individuals and between groups.

| | DPD T1 | | | DPD T2 | | | DPD T3 | | |
|---------------|------------|------|---------|-------------|------|---------|-------------|------|---------|
| | Mean (SD) | SE | P value | Mean (SD) | SE | P value | Mean (SD) | SE | P value |
| PAOO Group | 3.86 (1.1) | 0.49 | 0.233 | 6.38(3.03) | 1.35 | 0.614 | 3.9 (0.98) | 0.43 | 0.289 |
| Control Group | 7.46(6.1) | 2.7 | --- | 7.88 (5.66) | 2.51 | --- | 4.48 (0.48) | 0.25 | --- |

DISCUSSION

Periodontally Accelerated Osteogenic Orthodontics was developed to accelerate tooth movement and thus reduces treatment time and improves periodontal status, showing promising results (Wilcko *et al.*, 2001, 2003, 2008).

In this clinical trial, the total treatment time for the test group was 8.2 ± 3.3 months and for the control group it was 13.4 ± 7.3 months. These results demonstrate that while using this therapy with the protocol described, an acceleration of dental movement is achieved. This acceleration might be due to the RAP, which is a complex physiological process that includes rapid bone remodeling and loss of regional bone density, which increases tissue reorganization and healing by means of a transitory increase of localized bone resorption and further remodeling (Frost). It has been suggested that RAP in humans starts few days after surgery, peaks are present between the first and second months, and it can take from 6 to more than 24 months to decrease (Yaffe *et al.*, 1994).

Using the DamonTM system, a passive self-ligating system that reduces friction with the possibility of having a treatment plan that allows the early use of elastics, an adequate planning of torque selection and bracket positioning could create a synergy with these physiological postoperative effects caused by RAP helping to create a more efficient orthodontic treatment.

Additionally, the use of high-tech arch wires during the alignment and leveling phase allows the orthodontist to take advantage of the biological dynamic acceleration of tooth movement, taking in consideration the increase of bone turnover after it has been altered mechanically (Frost).

According to Murphy *et al.* the orthodontic tissue engineering permits the bending of bone, a situation

that opens a new perspective in the traditional orthodontic "Pressure –tension" hypothesis to explain bone modeling.

In this way you can elicit a kind of compensatory appositional osteogenesis with the same physiological response as SAD, but nonsurgically and over a long period of time with Normal Orthodontic mechanics. In accord with this, the surgical alteration of the alveolus bony form is simply an acceleration of the normal physiologic processes.

The treatment outcome of the orthodontic procedure was assessed and scored with the standardized measuring gauge according to the protocol provided by the American Board of Orthodontics (ABO) (Casko *et al.*, 1998) and all of them passed the examination (Fig. 5).

When considering the technical aspects of periodontal reconstructive procedures, two major factors seem to be important for a successful outcome. One is to eliminate or, to a great extent, reduce the chances of post-surgical infection and contamination of the blood clot and, possibly, the implanted biomaterial, which would unavoidably lead to an impaired healing outcome. The second is to minimize the postoperative soft tissue recession on the interproximal and buccal aspects of the treated tooth, with the result of compromising the preexisting esthetic impairments, loss of interdental papilla may result in phonetic problems and food impaction (Trombelli *et al.*, 2009). Recently new flap designs for reconstructive procedures have also been proposed to minimize the surgical trauma, leading to a decrease in post-surgical complications and patient discomfort (Trombelli *et al.*; Harrel, 1990; Cortellini & Tonetti, 2007). They are based on a minimally invasive approach with a flap elevation only on one side (buccal or lingual) leaving the soft

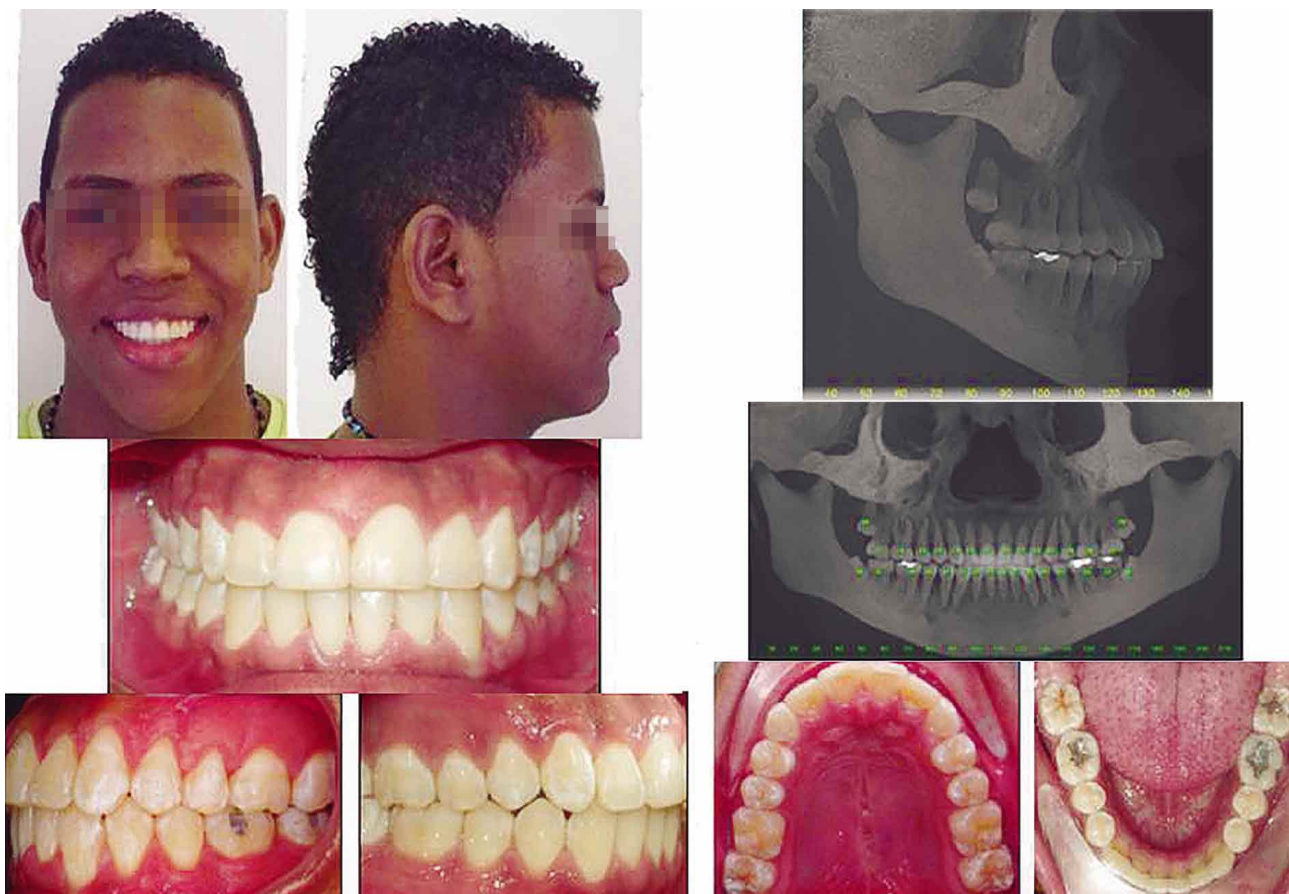

Fig. 5. The treatment outcome of the orthodontic procedure was assessed and scored with the standardized measuring gauge according to the protocol provided by the American Board of Orthodontics (ABO).

tissues on the opposite side intact, facilitating flap repositioning and suturing with the undetached oral papilla thus optimizing wound closure for primary intention. Moreover, by leaving a great volume of supracrestal soft tissues intact, better preservation of the blood supply in the interdental area may eventually occur (Binderman *et al.*, 2001; Nobuto *et al.*, 2003, 2005).

We decided to perform a surgical technique only in the buccal flap with a lower risk of developing gingival or papilla recession, and to simultaneously take advantage of the corticotomy facilitated orthodontics, localizing the interproximal bone cuts and bone graft in the buccal alveolar plate exclusively.

The periodontal parameters studied showed that while keeping a lower plaque level, there was no difference between T2-T1 periodontal variables in either group. Gingival recession was 0.49 ± 0.26 mm at T1 and 0.42 ± 0.3 mm at T2 in the Test Group. Gingival recession was 0.55 ± 0.31 mm at T1 and 1.19 ± 0.24 mm at T2 in the control Group. These results confirm that

corticotomy-facilitated orthodontics is a safe procedure for periodontal tissue as conventional orthodontic treatment (Düker, 1975; Nishida *et al.*, 1986; Wilcko *et al.*, 2001).

Biochemical markers of bone turnover reflect the process involved in remodeling and are, therefore, useful in the management of metabolic bone diseases. Biochemical markers are noninvasive and can reveal acute changes in bone turnover. In order to be useful, an ideal biochemical marker of bone turnover should be specific for one of the metabolic processes in the bone. Its mode of clearance, metabolism and plasma half-life should be known and it should be easily measurable and stable in serum or urine (Swaminathan, 2001).

Collagen is stabilized by the formation of covalent cross-links between the end of one collagen molecule and the helical portion of the adjacent collagen molecule. There are two major cross-link molecules, Pyridinoline (PYD) and Deoxypyridinoline (DPD) (Robins, 1999). Cross-links are formed extra-cellularly after the

deposition of collagen molecules into the matrix and they are released from bone only during bone resorption or collagen breakdown. PYD is widely distributed in connective tissue including bone and cartilage (Watts, 1999), the highest concentration being in cartilage. On the other hand, DPD is present in bone, dentine, aorta and ligaments (Swaminathan).

DPD constitutes about 21 % of the total cross-links in bone collagen (Calvo, 1996). It is thought that PYD and DPD are not catabolized in the liver but that part of the pyridinoline cross-links may be cleared through the liver (Delmas, 1995). As cross-link molecules are only found in mature collagen, the excretion of these molecules in the urine reflects degradation of mature collagen and does not represent newly formed bone collagen (Watts). There is extensive literature suggesting that the excretion of cross-links, especially DPD, is a good marker of bone resorption (Eastell *et al.*, 1990; James *et al.*, 1996). The excretion of collagen cross-links in urine increases in osteoporosis and in situations where bone resorption is increased, such as in hyperparathyroidism and hyperthyroidism. A positive correlation with other indices of bone resorption such as histomorphometry, has been shown (Eastell *et al.*).

In this research, the DPD values were variable between individuals. In most patients in the experimental group, DPD values increased between T1 and T2, and decreased in T3, almost to the same level that they were in the first measurement. In the control group the DPD values of most patients remained stable during all

the measurements. However, the DPD value of patient number 1 in T2 increased significantly without a physiologic explanation. The DPD value in T1 of patient number 2 was atypical, maybe due to a recent rhinoplasty.

These results show that DPD is potentially important in certain group of patients, and could be used as a bone turnover marker. It is important to work efficiently during the window period in this type of approach.

CONCLUSIONS

1. There is a reduction in treatment time for this group of patients undergoing Periodontally Accelerated Osteogenic Orthodontics with Damon Q Brackets.
2. There is no difference in the periodontal condition between Periodontally Accelerated Osteogenic Orthodontics and conventional orthodontics in this group of patients.
3. DPD is potentially important in certain group of patients, and could be used as a bone turnover marker.

ACKNOWLEDGMENTS

Amadeus Scan for the support with the CBCT of the patients and Zimplant (Zimmer Dental Colombia) for the donation of Puros™ Bone Allograft.

ARISTIZABAL, J. F.; BELLAIZA, W.; ORTIZ, M. A. & FRANCO, L. Efectos clínicos y sistémicos de ortodoncia osteogénica periodontalmente acelerada: un estudio piloto. *Int. J. Odontostomat.*, 10(1):119-127, 2016.

RESUMEN: El objetivo de este estudio fue describir los efectos periodontales y el tiempo de tratamiento de ortodoncia osteogénica periodontalmente acelerada (OOPA) y para determinar si desoxipiridinolina podría ser utilizado como un marcador bioquímico de recambio óseo en pacientes sometidos a OOPA. Se estudiaron 5 pacientes sometidos a OOPA (hombres, edad media de 29,6±9,8 años) y 5 pacientes control sometidos a ortodoncia de autoligado (hombres, edad media de 28,5±6,3 años). Todos los pacientes fueron evaluados utilizando radiografías panorámicas y laterales, tomografía computadorizada de haz cónico, y luego distribuidos aleatoriamente en grupos experimentales y de control. Ambos grupos fueron sometidos a la ortodoncia de autoligado utilizando dispositivos ortodónticos Damon Q. Sólo el grupo experimental fue sometido a OOPA. Los pacientes fueron evaluados periodontalmente en T1 (antes de la cirugía y el movimiento de ortodoncia) y T2 (después de un tratamiento de ortodoncia). El tiempo total de tratamiento para el grupo experimental fue de 8,2±3,3 meses y para el grupo control 13,4±7,3 meses. No hubo diferencias entre las variables periodontales T2-T1 en cualquiera de los grupos. La recesión gingival en el grupo experimental fue de 0,49±0,26 mm en T1 y 0,42±0,3 mm en T2. En el grupo control, la recesión gingival fue 0,55±0,31 mm en T1 y 1,19±0,24 mm en T2. Los niveles de desoxipiridinolina en orina mostraron gran variación entre individuos y entre grupos. Hubo una reducción en el tiempo de tratamiento para los pacientes sometidos OOPA con dispositivos ortodónticos Damon Q. No hubo diferencia en la condición periodontal entre pacientes sometidos a OOPA y ortodoncia convencional.

PALABRAS CLAVE: ortodoncia osteogénica periodontalmente acelerada (OOPA), ortodoncia de autoligado, Wilckodontics, corticotomía, desoxipiridinolina, Fenómeno aceleratorio regional (RAP).

REFERENCES

- Binderman, I.; Adut, M.; Zohar, R.; Bahar, H.; Faibish, D. & Yaffe, A. Alveolar bone resorption following coronal versus apical approach in a mucoperiosteal flap surgery procedure in the rat mandible. *J. Periodontol.*, 72(10):1348-53, 2001.
- Blumsohn, A. & Eastell, R. The performance and utility of biochemical markers of bone turnover: do we know enough to use them in clinical practice? *Ann. Clin. Biochem.*, 34(Pt. 5):449-59, 1997.
- Buschang, P. H.; Campbell, P. M. & Ruso, S. Accelerating tooth movement with corticotomies: Is it possible and desirable? *Semin. Orthod.*, 18(4):286-94, 2012.
- Calvo, M. S.; Eyre, D. R. & Gundberg, C. M. Molecular basis and clinical application of biological markers of bone turnover. *Endocr. Rev.*, 17(4):333-68, 1996.
- Casko, J. S.; Vaden, J. L.; Kokich, V. G.; Damone, J.; James, R. D.; Cangialosi, T. J.; Riolo, M. L.; Owens, S. E. Jr. & Bills, E. D. Objective grading system for dental casts and panoramic radiographs. American Board of Orthodontics. *Am. J. Orthod. Dentofacial Orthop.*, 114(5):589-99, 1998.
- Cho, K. W.; Cho, S. W.; Oh, C. O.; Ryu, Y. K.; Ohshima, H. & Jung, H. S. The effect of cortical activation on orthodontic tooth movement. *Oral Dis.*, 13(3):314-9, 2007.
- Cortellini, P. & Tonetti, M. S. A minimally invasive surgical technique with an enamel matrix derivative in the regenerative treatment of intra-bony defects: a novel approach to limit morbidity. *J. Clin. Periodontol.*, 34(1):87-93, 2007.
- Delmas, P. D. *Biochemical Markers for the Assessment of Bone Turnover*. In: Riggs, B. L. & Melton, L. J. III (Eds.). *Osteoporosis: Etiology, Diagnosis and Management*. 2nd ed. Philadelphia, Lippincott-Raven, 1995. pp.319-33.
- Düker, J. Experimental animal research into segmental alveolar movement after corticotomy. *J. Maxillofac. Surg.*, 3(2):81-4, 1975.
- Eastell, R.; Russell, R. G. G. & Reeve, J. *Urinary Collagen Cross-Links are Highly Correlated with Radioisotopic Measurements of Bone Resorption*. In: Christiansen, C. & Overgaard, K. (Eds.). *Osteoporosis 1990*. Third International Symposium on Osteoporosis, 14-20 October 1990. Copenhagen, Osteopress, 1990. pp.469-77.
- Frost, H. M. The regional acceleratory phenomenon: a review. *Henry Ford Hosp. Med. J.*, 31(1):3-9, 1983.
- Harrel, S. K. A minimally invasive surgical approach for periodontal regeneration: surgical technique and observations. *J. Periodontol.*, 70(12):1547-57, 1990.
- Hassan, A. H.; Al-Fraidi, A. A. & Al-Saeed, S. H. Corticotomy-assisted orthodontic treatment: review. *Open Dent. J.*, 4:159-64, 2010.
- Iino, S.; Sakoda, S.; Ito, G.; Nishimori, T.; Ikeda, T. & Miyawaki, S. Acceleration of orthodontic tooth movement by alveolar corticotomy in the dog. *Am. J. Orthod. Dentofacial Orthop.*, 131(4):448.e1-8, 2007.
- James, I. T.; Walne, A. J. & Perrett, D. The measurement of pyridinium crosslinks: a methodological overview. *Ann. Clin. Biochem.*, 33(Pt. 5):397-420, 1996.
- Mathews, D. P. & Kokich, V. G. Managing treatment for the orthodontic patient with periodontal problems. *Semin. Orthod.*, 3(1):21-38, 1997.
- Mueller, M.; Schilling, T.; Minne, H. W. & Ziegler, R. A systemic acceleratory phenomenon (SAP) accompanies the regional acceleratory phenomenon (RAP) during healing of a bone defect in the rat. *J. Bone Miner. Res.*, 6(4):401-10, 1991.
- Murphy, N. C.; Bissada, N. F.; Davidovitch, Z.; Kucska, S.; Bergman, R. T.; Dashe, J. & Enlow, D. H. Corticotomy and tissue engineering for orthodontists: A critical history and commentary. *Semin. Orthod.*, 18(4):295-307, 2012.
- Nishida, M.; Iizuka, T.; Itoi, S.; Hyo, Y. & Ono, T. Clinical study of corticotomy by Kule's method. *J. Jpn. Oral Surg. Soc.*, 3:81-4, 1986.
- Nobuto, T.; Imai, H.; Suwa, F.; Kono, T.; Suga, H.; Jyoshi, K. & Obayashi, K. Microvascular response in the periodontal ligament following mucoperiosteal flap surgery. *J. Periodontol.*, 74(4):521-8, 2003.
- Nobuto, T.; Suwa, F.; Kono, T.; Taguchi, Y.; Takahashi, T.; Kanemura, N.; Terada, S. & Imai, H. Microvascular response in the periosteum following mucoperiosteal flap surgery in dogs: angiogenesis and bone resorption and formation. *J. Periodontol.*, 76(8):1346-53, 2005.
- Ong, M. M. & Wang, H.L. Periodontic and orthodontic treatment in adults. *Am. J. Orthod. Dentofacial Orthop.*, 122(4):420-8, 2002.

Robins, S. P. Biochemical markers of bone metabolism.
CPD Bull. Clin. Biochem., 1(4):116-21, 1999.

Swaminathan, R. Biochemical markers of bone turnover.
Clin. Chim. Acta, 313(1-2):95-105, 2001.

Trombelli, L.; Farina, R.; Franceschetti, G. & Calura, G. Single-flap approach with buccal access in periodontal reconstructive procedures. *J. Periodontol.*, 80(2):353-60, 2009.

Wang, L.; Lee, W.; Lei, D. L.; Liu, Y. P.; Yamashita, D. D. & Yen, S. L. Tissue responses in corticotomy- and osteotomy-assisted tooth movements in rats: histology and immunostaining. *Am. J. Orthod. Dentofacial Orthop.*, 136(6):770.e1-11, 2009.

Wang, L. & Yen, S. Histological analysis of corticotomy and osteotomy-assisted tooth movement in a rat model. *J. Oral Maxillofac. Surg.*, 66(8):41-2, 2008.

Watts, N. B. Clinical utility of biochemical markers of bone remodeling. *Clin. Chem.*, 45(8 Pt. 2):1359-68, 1999.

Weiss, S.; Baumgart, R.; Jochum, M.; Strasburger, C. J. & Bidlingmaier, M. Systemic regulation of distraction osteogenesis: a cascade of biochemical factors. *J. Bone Miner. Res.*, 17(7):1280-9, 2002.

Wilcko, M. T.; Wilcko, W. M. & Bissada, N. F. An evidence-based analysis of periodontally accelerated orthodontic and osteogenic techniques: A synthesis of scientific perspectives. *Semin. Orthod.*, 14(4):305-16, 2008.

Wilcko, W. M.; Ferguson, D. J.; Bouquot, J. E. & Wilcko, T. Rapid orthodontic decrowding with alveolar augmentation: Case report. *World J. Orthod.*, 4(3):197-205, 2003.

Wilcko, W. M.; Wilcko, T.; Bouquot, J. E. & Ferguson, D. J. Rapid orthodontics with alveolar reshaping: two case reports of decrowding. *Int. J. Periodontics Restorative Dent.*, 21(1):9-19, 2001.

Yaffe, A.; Fine, N. & Binderman, I. Regional accelerated phenomenon in the mandible following mucoperiosteal flap surgery. *J. Periodontol.*, 65(1):79-83, 1994.

Correspondence to:

Dr. Juan Fernando Aristizábal
Orthodontist

Assistant professor and head, Department of Orthodontics
Universidad del Valle
Cra 100 # 11-60 office 505
Cali
COLOMBIA

Email: juanferaristi@hotmail.com

Received: 22-10-2015

Accepted: 03-02-2016