

# Injectable Composite Resin Technique: An Alternative for Anterior Esthetic Restorations - Case Report

Técnica de Resina Compuesta Inyectable: Una Alternativa para Restauraciones Estéticas Anteriores - Reporte de Caso

Tatiana Cursino Pereira<sup>1</sup>; Jefferson David Melo de Matos<sup>2</sup>;  
Victor Ruano<sup>1</sup>; Marco Antonio Bottino<sup>2</sup> & Eduardo Bresciani<sup>1</sup>

---

PEREIRA, T. C.; MATOS, J. D. M.; RUANO, V.; BOTTINO, M. A. & BRESCIANI, E. Injectable composite resin technique: An alternative for anterior esthetic restorations - case report. *Int. J. Odontostomat.*, 17(3):245-250, 2023.

**ABSTRACT:** This article aims to describe a clinical case of the use of the injectable restorative technique with composite resin in a patient with an esthetic complaint in the anterior teeth. Producing direct restorations in anterior teeth when performed with composite resin demands a long clinical time. Results often depend on the operator's ability to reproduce proper form, function, and esthetics. Lately, the versatility of composite resins has increased. As this material evolved, new techniques were introduced to simplify the restorative process and save time. The restorative technique with injectable fluid composite resin, in addition to delivering faster and with a certain ease, is capable of increasing the predictability of treatment results. However, it is known that flowable resins have lower wear resistance and color stability compared to conventional resins. Thus, a version of this material with a higher filler content in its composition was introduced to the market, to improve wear resistance and gloss retention. Long-term studies evaluating the use of low-viscosity resins are needed. The injectable technique can accurately reproduce the morphology obtained in the wax-up of the case, generating a satisfactory esthetic and functional result. Despite simplifying the fabrication of restorations when compared to the conventional technique, it is still necessary for the operator to have some experience and aptitude. The clinical time for the production of restorations has been considerably reduced. The material showed good flow, shine, and polish in the immediate result. However, the finishing and polishing of the restorations required a longer clinical period than usual and in the short-term follow-up, flaws in the gingival margins and a new finishing and polishing procedure were necessary. Therefore, the technique described in this article can be considered a restorative alternative, but it is still not able to replace the traditional method of making previous esthetic restorations.

**KEY WORDS:** resin composite, flowable resin composite, injectable resin composite, injectable resin technique, wax up.

---

## INTRODUCTION

As an attempt to minimize the disadvantages of acrylic resins used in the 1940s, composite resins were introduced to conservative dentistry. In 1955, Buonocore improved the adhesion of acrylic resins to enamel through the use of phosphoric acid. In 1962, Bowen developed the Bis-GMA monomer, which was later polymerized by an ultraviolet light source (Hervás-García *et al.*, 2006; Matos *et al.*, 2021). The increase in composite resin use was

mainly due to the bond strength of this material with the dental substrate. As their mechanical and optical properties constantly evolve, resins have overcome limitations and become more versatile (Ikeda *et al.*, 2009; Coachman *et al.*, 2020).

However, the use of this material for making direct restorations in anterior teeth demands a long clinical time. In addition, results are highly dependent

<sup>1</sup> Department of Operative Dentistry, São Paulo State University (Unesp), Institute of Science and Technology, São José dos Campos - SP, Brazil.

<sup>2</sup> Department of Biomaterials, Dental Materials and Prosthodontics, São Paulo State University (Unesp), Institute of Science and Technology, São José dos Campos - SP, Brazil.

on the operator's ability to reproduce the proper form, function, and esthetics. Furthermore, the reproduction of well-adapted battlements and contours using conventional resins can be a challenge for clinicians. Therefore, professionals sometimes opt for the production of indirect restorations. However, working indirectly also has its disadvantages, as it increases the cost and time required to resolve the case (Coachman *et al.*, 2020; Ypei Gia *et al.*, 2021).

New clinical techniques were introduced to facilitate the application of direct restorative materials, save time, and obtain satisfactory esthetic and functional results. Mockups using acrylic resin and transparent index with injected fluid resin have become popular for making provisionals for anterior teeth (Gouveia *et al.*, 2017). Flowable resins have low viscosity and offer high wettability of the tooth surface, ensuring penetration into all irregularities and the formation of layers of a minimum thickness (Hervás-García *et al.*, 2006; Matos *et al.*, 2021). Studies conducted to improve the mechanical properties of flowable resins resulted in the addition of nanoparticles to their composition. Such an improvement did not affect the material handling characteristics. However, studies have concluded that such resins have good polishing but reduced wear resistance. Therefore, fluid resins are indicated for low-stress areas (Coachman *et al.*, 2020).

The injectable resin composite restorative technique enables agility and simplicity of execution. It consists of a copy of the wax-up that is reproduced on a transparent matrix with small holes for the material to flow into the tooth. The approach is conservative and additive that is, there is no need to remove healthy tooth structure (Terry & Powers, 2014). When compared to direct and indirect restoration techniques, the injectable technique is the least sensitive. Therefore, a clinician's ability and clinical time can be considerably decreased. Thus, the cost of the procedure is also reduced (Coachman *et al.*, 2020; Ypei-Gia *et al.*, 2020).

Some factors, such as gloss, surface roughness, and color stability, are essential for anterior restoration success. An esthetic restorative material must simulate natural tooth color and maintain it over time (Lai *et al.*, 2018). Although it is known that some of the flowable resin's disadvantages are low wear resistance and color stability when compared to conventional resin

composites (Kim *et al.*, 2002; Karadas, 2016; Nair *et al.*, 2017). With the constant evolution of flowable resin formulations, a new version of this material with a high load in the composition was introduced into the market with the promise of increased wear resistance and gloss maintenance. However, there are rare studies in the literature that evaluate this material over the long term (Terry & Powers, 2014). Thus, this article aims to report a clinical case of an injectable resin composite restorative technique on a patient with an esthetic complaint on the anterior teeth.

## CASE REPORT

A 26-year-old male patient presented to São Paulo State University, in São José dos Campos. The patient reported being dissatisfied with the esthetic of his anterior teeth. After clinical examination, stained resin restorations, wear, and fractures were observed (Figs. 1-6). As a treatment plan, it was determined to perform superior esthetic restorations by the injectable technique from teeth 13 to 23 and restorations by the conventional technique with composite resin in the premolars of both Hemi-arches.

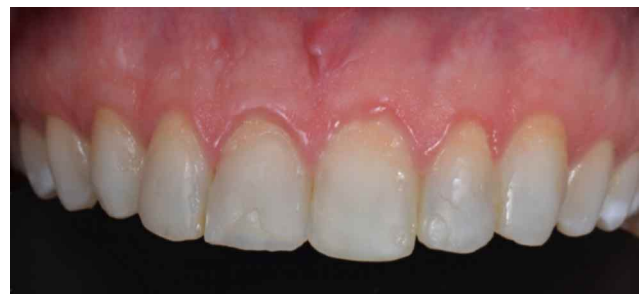

Fig. 1. Initial photos from the patient's teeth.

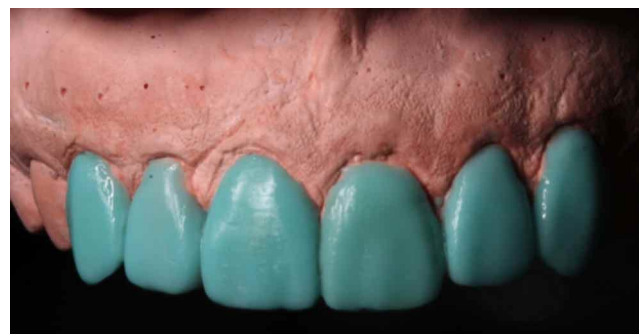

Fig. 2. Wax-up performed for producing the transparent index for the restorations.

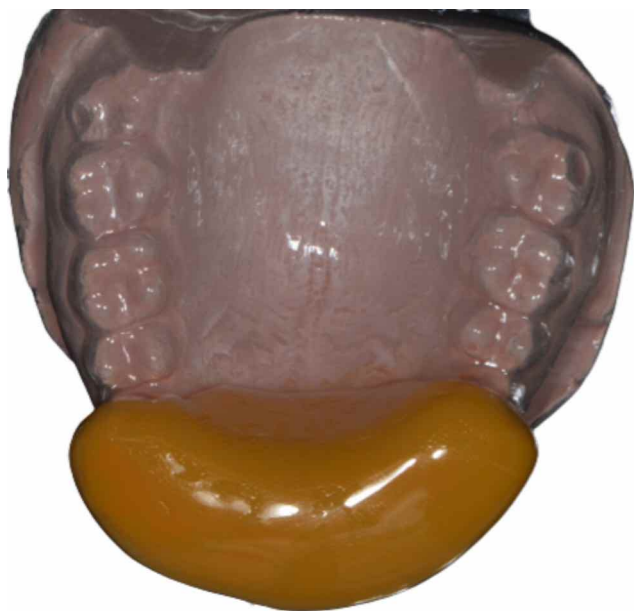


Fig. 3. Acetate plate.

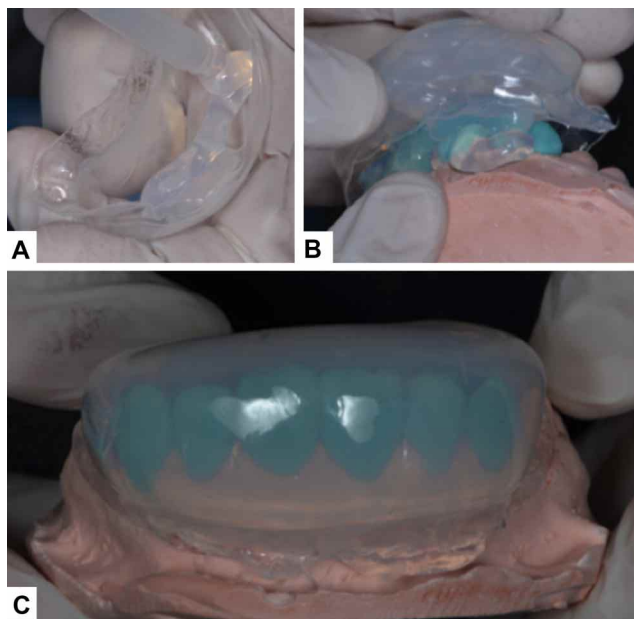


Fig. 4. A. silicone application on the acetate plate; B. acetate plate being adapted to the wax-up; C: silicone index adapted to the wax-up guaranteeing 2mm thickness.

Previous restorations were removed with SofLex discs (3M). Prophylaxis was performed on the patient, as well as modified isolation with a rubber dam on the superior teeth. After isolation, protection with Teflon (Isotope, TVD) was made on the tooth that wasn't supposed to be restored at this moment. Enamel etching with phosphoric acid at 35 % (Ultra Etch, Ultradent) (Fig. 7) was applied, rinsed, and dried. For the adhesion system, Single Bond Universal (3M) was

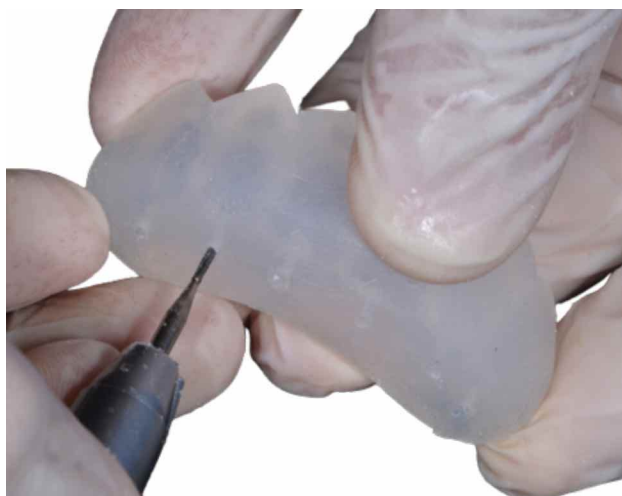

Fig. 5. Created perforations to insert the tip of the syringe of the flowable resin composite.

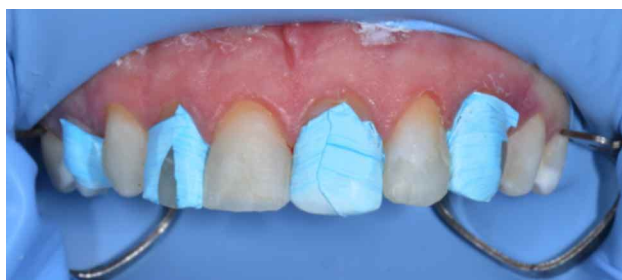

Fig. 6. Isolation of the teeth to be restored and separation of the other teeth with a Teflon band.

used, and it was photopolymerized for 20 seconds (Emmiter A Fit – Schuster). The index was positioned in the mouth and a flowable injectable resin syringe was inserted into the incisal perforations created on the index (Fig. 8). After the injection of the flowable resin (G-aerial Universal Flo BW, GC Corporation) on each tooth, photopolymerization was realized on the labial and lingual faces for 30 seconds on each.

Before the procedure was repeated on the other group of teeth, the excess material was removed with a scalpel (no 12) and sandpaper so the injected resin wouldn't adhere to it. Protection of the already restored tooth was made with Teflon (Isotope, TVD) and the procedure described earlier was repeated. After the execution of it, finishing and polishing were performed, as well as eventual occlusal adjustments. For finishing and polishing, SofLex discs (3M) and interproximal sandpaper (3M) were used. Occlusion was verified with carbon paper 100  $\mu$ m (Bausch, Colônia), where the patient performed protrusive, retrieve, and lateral movements. For polishing, finishing rubbers (Jiffy Verde – Ultradent; Diacomp twist EVE-Odontomega) were

used. The patient returned after a week for eventual adjustments and the confection of the premolar restorations. Finally, extra oral registers were made with a digital camera (Fig. 9).

After a week, the patient returned for a follow-up appointment. There could be observed some staining in the cervical area, near the gingival margin. A new finishing and polishing procedure was executed with the same materials described before. Regions that presented a lack of material were sealed with the flowable resin. These procedures were performed to improve the restoration's esthetic and longevity.

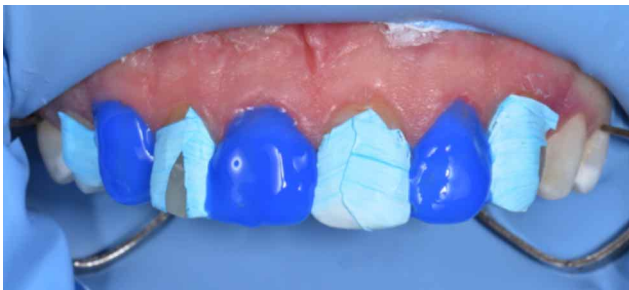

Fig. 7. Phosphoric acid etching.

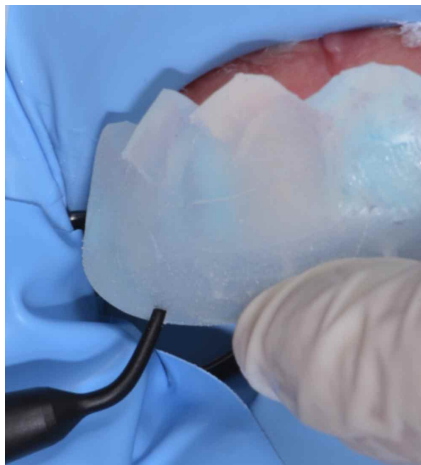

Fig. 8. Silicone index and the tip of the flowable resin positioned on the incisal's perforations.

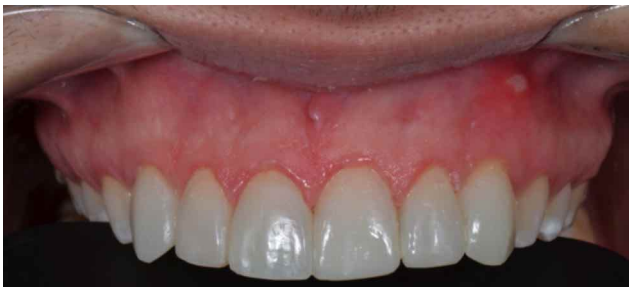

Fig. 9. Final photos of the patient's teeth after finishing and polishing.

## DISCUSSION

Based on the possibility of performing a diagnostic wax-up, the injectable resin technique increases the predictability of results. The fidelity to the dental anatomy achieved by the transparent matrix and its reproduction through the use of low impression precision corroborates the high precision results (Coachman *et al.*, 2020). Fluid resins have the advantage of adapting the material to the margins and filling the compost materials. However, despite all the continuous efforts to improve the resin's properties, they present a reduced number of fillers when compared to conventional resin. This characteristic interferes with the mechanical properties of this material, causing greater susceptibility to wear and reduced polishing quality and color stability (Terry & Powers, 2014; Karadas, 2016; Nair *et al.*, 2017).

The injectable resin has higher flexural strength compared to other fluid materials, as well as lower flexural modulus and greater resilience (Imai *et al.*, 2019). However, the success of restorations mainly depends on their appearance and color stability. One of the most common esthetic flaws encountered by clinicians is the discoloration of anterior restorations. Situations like this generate patient dissatisfaction and the need for retreatment. This fact is an inconvenience caused, given the extra time and money that is spent on both sides (Abd-Elhamid & Mosallam, 2010). Discoloration of restorations can be extrinsic or intrinsic. Extrinsic causes include plaque buildup and surface staining, which degrades the restoration surface and generates penetration and absorption of coloring agents into the composite resin. Intrinsic causes can be related to physicochemical reactions that take place inside the restoration (Powers *et al.*, 1978; Dietschi *et al.*, 1994).

The degree of color change can also be affected by the structure of the composite resin, the characteristics of the filler particles, the degree of polymerization, and the water sorption of the material. If the composite resin can absorb water, then it is also capable of absorbing other fluids that cause discoloration (Garoushi *et al.*, 2013; Karadas, 2016). For the removal of surface stains from composite resin restorations, tooth hygiene and the execution of polishing protocols performed by the dentist are the most frequently used options. However, sometimes polishing procedures are not able to achieve the original appearance of the restoration. This is because the

penetration is deep and the stains are not superficial. In some cases, polishing can even lead to the removal of layers from the resin surface, increasing the surface roughness of the restoration (Türkün & Türkün, 2004; Abd-Elhamid & Mosallam, 2010).

Fluid materials can have different amounts of inorganic content, ranging from 61 to 71 % of their composition. The resin used in this clinical case has a higher amount of filler than other fluid resins available on the market and, for this reason, covers a greater number of indications to be used. However, despite having a higher number of fillers and showing an indication of universal use, studies observed that when simulating occlusal stress, flowable resins showed significantly reduced values when compared to bulk-fill resins (Ujiie *et al.*, 2020). Therefore, low-viscosity resins need to have their clinical performance and longevity investigated and compared to regular viscosity materials (Torres *et al.*, 2014). Directly fabricated restorations, whether injectable or not, have limitations in terms of wear. In this case, the patient had bruxism. Thus, before treatment, the professional explained the limitations of the case to the patient, and a plate to protect the teeth was made at the end of the treatment.

Although the technique aims to simplify the restorative process, some limitations were observed. The technique consists of a series of steps that, if the operator is inexperienced, can take a long time to perform. The adequacy of the interproximal spaces and the removal of excess material that is generated after the light curing of the material can consume a lot of clinical time (Ges̃takovski, 2019). If a lot of finishing is needed, it can lead to a de-characterization of the anatomy produced by the wax-up.

### Final considerations

It can be concluded from this study that: The injectable technique can accurately reproduce the morphology obtained in the wax-up of the case, generating a satisfactory esthetic and functional result. Despite its simplification when compared to the conventional technique, it is still necessary for the operator to have some skill. The clinical time for making the restorations was considerably reduced. However, much of the service was spent on achieving the final finishing and polishing, which was considered ideal. The fluid resin used showed good flow, gloss, and polishing in the immediate result. However, in the short-term follow-up, failures can be observed in the

restoration close to the gingival margin, suggesting low strength when in thinner thickness. It was also observed that there was a need for regular follow-ups to guarantee color stability and greater treatment longevity. Therefore, the technique described in this article can be considered a restorative alternative, but it is still not able to replace the traditional restorative technique for anterior teeth.

**ACKNOWLEDGMENTS.** This research was funded by São Paulo Research Foundation (FAPESP – grant numbers 2019/24903-6, and 2021/11499-2).

---

**PEREIRA, T. C.; MATOS, J. D. M.; RUANO, V.; BOTTINO, M. A. & BRESCIANI, E.** Técnica de resina compuesta inyectable: Una alternativa para restauraciones estéticas anteriores - reporte de caso. *Int. J. Odontostomat.*, 17(3):245-250, 2023.

**RESUMEN:** Este artículo tiene como objetivo describir un caso clínico del uso de la técnica restauradora inyectable con resina compuesta en un paciente con una queja estética en los dientes anteriores. Producir restauraciones directas en dientes anteriores cuando se realizan con resina compuesta demanda un largo tiempo clínico. Los resultados a menudo dependen de la capacidad del operador para reproducir la forma, la función y la estética adecuadas. Últimamente, la versatilidad de las resinas compuestas ha aumentado. A medida que este material evolucionó, se introdujeron nuevas técnicas para simplificar el proceso de restauración y ahorrar tiempo. La técnica restauradora con resina compuesta fluida inyectable, además de una entrega más rápida y segura, es capaz de aumentar la previsibilidad de los resultados del tratamiento. Sin embargo, se sabe que las resinas fluidas tienen menor resistencia al desgaste y estabilidad del color en comparación con las resinas convencionales. Así, se introdujo en el mercado una versión de este material con un mayor contenido de relleno en su composición, con el objetivo de mejorar la resistencia al desgaste y la retención del brillo. Se necesitan estudios a largo plazo que evalúen el uso de resinas de baja viscosidad. La técnica inyectable es capaz de reproducir fielmente la morfología obtenida en el encerado del caso, generando un resultado estético y funcional satisfactorio. A pesar de simplificar la fabricación de restauraciones en comparación con la técnica convencional, todavía es necesario que el operador tenga cierta experiencia y aptitud. El tiempo clínico para la producción de restauraciones se ha reducido considerablemente. El material mostró buena fluidez, brillo y pulido en el resultado inmediato. Sin embargo, el acabado y pulido de las restauraciones requirió de un período de tiempo clínico más largo de lo habitual y en el seguimiento a corto plazo, fueron necesarios defectos en los márgenes gingivales y un nuevo procedimiento de acabado y pulido. Por lo tanto, la técnica descrita en este artículo puede considerarse una al-

ternativa restauradora, pero aún no es capaz de reemplazar el método tradicional de realizar restauraciones estéticas previas.

**PALABRAS CLAVE: compuesto de resina, compuesto de resina fluido, compuesto de resina inyectable, técnica de resina inyectable, encerado.**

## REFERENCES

- Abd-Elhamid, M. & Mosallam, R. Effect of bleaching versus repolishing on colour and surface topography of stained resin composite. *Aust. Dent. J.*, 55(4):390-8, 2010.
- Coachman, C.; De Arbeloa, L.; Mahn, G.; Sulaiman, T. A. & Mahn, E. An Improved direct injection technique with flowable composites. A Digital Workflow Case Report. *Oper. Dent.*, 45(3):235-42, 2020.
- Dietschi, D.; Campanile, G.; Holz, J. & Meyer, J. M. Comparison of the color stability of ten new-generation composites: an in vitro study. *Dent. Mater.*, 10(6):353-62, 1994.
- Garoushi, S.; Lassila, L.; Hatem, M.; Shembesh, M.; Baady, L.; Salim, Z. & Vallittu, P. Influence of staining solutions and whitening procedures on discoloration of hybrid composite resins. *Acta Odontol. Scand.*, 71(1):144-50, 2013.
- Ges'takovski, D. The injectable composite resin technique: minimally invasive reconstruction of esthetics and function. Clinical case report with 2-year follow-up. *Quintessence Int.*, 50(9):712-9, 2019.
- Gouveia, T. H. N.; Theobaldo, J. D.; Vieira-Junior, W. F.; Lima, D. A. N. L. & Aguiar, F. H. B. Esthetic smile rehabilitation of anterior teeth by treatment with biomimetic restorative materials: a case report. *Clin. Cosmet. Investig. Dent.*, 9:27-31, 2017.
- Hervás-García, A.; Martínez-Lozano, M. A.; Cabanes-Vila, J.; Barjau-Escribano, A. & Fos-Galve, P. Composite resins. A review of the materials and clinical indications. *Med. Oral Patol. Oral Cir. Bucal*, 11(2):E215-20, 2006.
- Ikeda, I.; Otsuki, M.; Sadr, A.; Nomura, T.; Kishikawa, R. & Tagami, J. Effect of filler content of flowable composites on resin-cavity interface. *Dent. Mater. J.*, 28(6):679-85, 2009.
- Imai, A.; Takamizawa, T.; Sugimura, R.; Tsujimoto, A.; Ishii, R.; Kawazu, M.; Saito, T. & Miyazaki, M. Interrelation among the handling, mechanical, and wear properties of the newly developed flowable resin composites. *J. Mech. Behav. Biomed. Mater.*, 89:72-80, 2019.
- Karadas, M. The effect of different beverages on the color and translucency of flowable composites. *Scanning*, 38(6):701-9, 2016.
- Kim, K. H.; Ong, J. L. & Okuno, O. The effect of filler loading and morphology on the mechanical properties of contemporary composites. *J. Prosthet. Dent.*, 87(6):642-9, 2002.
- Lai, G.; Zhao, L.; Wang, J. & Kunzelmann, K. H. Surface properties and color stability of dental flowable composites influenced by simulated toothbrushing. *Dent. Mater. J.*, 37(5):717-24, 2018.
- Matos, J. D. M.; Nakano, L. J. N.; Lopes, G. R. S.; Bottino, M. A.; Vasconcelos, J. E. L.; Jesus, R. H. & Maciel, L. C. Characterization of bulk-fill resin composites in terms of physical, chemical, mechanical and optical properties and clinical behavior. *Int. J. Odontostomat.*, 15(1):226-33, 2021.
- Nair, S. R.; Niranjana, N. T.; Jayasheel, A. & Suryakanth, D. B. Comparative Evaluation of Colour Stability and surface hardness of methacrylate based flowable and packable composite - In vitro study. *J. Clin. Diagn. Res.*, 11(3):ZC51-ZC54, 2017.
- Powers, J. M.; Dennison, J. B. & Lepeak, P. J. Parameters that affect the color of direct restorative resins. *J. Dent. Res.*, 57(9-10):876-80, 1978.
- Terry, D. & Powers, J. Using injectable resin composite: part one. *Int. Dent. Afr.*, 5:52-62, 2014.
- Torres, C. R. G.; Rêgo, H. M.; Perote, L. C.; Santos, L. F.; Kamozaqi, M. B.; Gutierrez, N. C.; Di Nicoló, R. & Borges, A. B. A split-mouth randomized clinical trial of conventional and heavy flowable composites in class II restorations. *J. Dent.*, 42(7):793-9, 2014.
- Türkün, L. S. & Türkün, M. Effect of bleaching and repolishing procedures on coffee and tea stain removal from three anterior composite veneering materials. *J. Esthet. Restor. Dent.*, 16(5):290-301, 2004.
- Ujiie, M.; Tsujimoto, A.; Barkmeier, W. W.; Jurado, C. A.; Villalobos-Tinoco, J.; Takamizawa, T.; Latta, M. A. & Miyazaki, M. Comparison of occlusal wear between bulk-fill and conventional flowable resin composites. *Am. J. Dent.*, 33(2):74-8, 2020.
- Ypei Gia, N. R.; Sampaio, C. S.; Higashi, C.; Sakamoto Jr., A. & Hirata, R. The injectable resin composite restorative technique: A case report. *J. Esthet. Restor. Dent.*, 33(3):404-14, 2021.

Corresponding author:  
Tatiana Cursino Pereira  
D.D.S.; M.D. Student.  
Post Graduate Student – Master Degree Program  
Department of Operative Dentistry  
São Paulo State University (Unesp)  
Institute of Science and Technology  
Avenida Engenheiro Francisco José Longo 777/778  
Jardim São Dimas, São José dos Campos – SP  
CEP: 12245000  
Sao Paulo  
BRAZIL

E-mail: matosjefferson19@gmail.com