

# Surgical Treatment of Oral Fibrous Hyperplasia with Diode Laser: An Integrative Review

Tratamiento Quirúrgico de la Hiperplasia Fibrosa Oral  
con Láser de Diodo: Una Revisión Integradora

Ana Livia Do Amaral; Mailon Cury Carneiro; Gustavo De Paula Almeida & Paulo Sérgio Da Silva Santos

DO AMARAL, A. L.; CARNEIRO, M. C.; ALMEIDA, G. P.; DA SILVA SANTOS, P. S. Surgical treatment of oral fibrous hyperplasia with diode laser: An integrative review. *Int. J. Odontostomat.*, 17 (2):136-141, 2023.

**ABSTRACT:** This study aimed to carry out an integrative review of the use of diode lasers in the treatment of oral fibrous hyperplasia in order to observe surgical efficacy, healing process, and main microscopic findings. The following databases—PubMed/MEDLINE, Embase, Virtual Health Library, Scopus, Web of Science, and gray literature—were searched without regard to the time of year or language. Diode laser treatment cases described in case reports and case series were included, but those who did not undergo microscopic analysis to confirm the diagnosis or who did not provide postoperative information were excluded. Twelve studies (64 patients) were included. Prevalence was observed for females (68.75 %, n=44). In view of the diagnosis, there was a prevalence of focal fibrous hyperplasia (79.68 %, n=51), followed by inflammatory fibrous hyperplasia (20.31 %, n=13). For surgical removal, a diode laser was used with a wavelength ranging from 808 to 960 nm, in continuous mode, and an average power of 2830 mW. In general, there were no intercurrents in the trans and postoperative periods and wound healing occurred by second intention, with excellent evolution. High-powered diode lasers can be an excellent therapeutic option for oral hyperplastic lesions. Long-term clinical trials should be conducted to determine laser setting parameters in various oral lesions.

**KEY WORDS:** hyperplasia, diode laser, laser therapy.

## INTRODUCTION

Inflammatory fibrous hyperplasia (IFH) and focal fibrous hyperplasia (FFH) are common alterations in the mouth defined as reactive lesions of the fibrous connective tissue in response to recurrent low-intensity irritations, often caused by local trauma. IFH is commonly associated with poorly fitting denture or partial denture edges (Canger *et al.*, 2009). FFH can also result from persistent trauma, from chronic nibbling of the mucosa, in addition to restorations with sharp edges and diastemas (Santos *et al.*, 2014; Ogbureke *et al.*, 2018).

Surgical excision with a scalpel is the gold standard for treating these lesions, although this method can lead to intraoperative bleeding, infection, and slow healing. Lasers of different wavelengths have significantly advanced in Dentistry and have proven to

be essential in oral soft tissue surgery, as they allow effective excision with great hemostasis and field visibility (Al-Otaibi & Al-Mohaya, 2020). In addition, lasers offer the patient greater postoperative comfort when compared to traditional scalpel procedures (Coluzzi, 2008).

The diode laser has become the most widely used in oral surgery due to its exceptional compactness, cost, ease of operation, and setup. In addition, the use of diode lasers reduces the need for anesthesia, regulates hemostasis, and provides a surgical site relatively free of bleeding and the need for sutures (Coluzzi, 2008; Derikvand *et al.*, 2016).

The goal of this integrative review was to assess the use of laser or diode in the treatment of these

lesions in order to visualize the surgical efficacy and the cicatricial pattern. This was done in light of the fact that diode laser surgery appears to be a good option for the treatment of oral diseases like IFH and FFH and that conventional treatment with scalpels can result in clinical complications. This study was motivated by the following question: "What are the benefits of diode laser surgery in terms of surgical effectiveness and healing pattern in patients with oral fibrous hyperplasia?"

## MATERIAL AND METHOD

**Survey question and eligibility criteria.** The subject of this integrative review was developed using a modified PICO strategy: (P) patients with oral fibrous hyperplasia (IFH or FFH), (I) surgical treatment with diode laser, (C) not applicable, and (O) surgical efficiency and standard of healing.

We included case reports and case series that provided information on patients diagnosed with a hyperplastic lesion located in any part of the oral mucosa directly associated with a specific trauma from poorly adapted partial or total removable dentures, biting habits or sucking habits; studies that did not report performing microscopic analysis to confirm the diagnosis were excluded.

Studies that described how to use the laser, including its type, wavelength, and power, were included as part of the intervention. The absence of this data led to exclusion from the investigation.

Studies that provided comprehensive information about the postoperative period (such as details about likely complications, symptomatology, and healing pattern) were included in the analysis of the results.

**Sources of information and research strategy.** PubMed/MEDLINE, Embase (via Elsevier), Virtual Health Library, Scopus, and Web of Science were the electronic databases used. In addition, the gray literature was used, which was based on the manual search of reference lists of relevant research, as well as the use of Google Scholar. The search strategy included terms linked to population (patients with oral fibrous hyperplasia) and intervention (use of diode laser), which were combined with Boolean operators, adapted for use in each of the bibliographic bases, along with specific filters. The database search strategy is

summarized in Supplementary Table I. There were no limits as to year or language of publication. All bases were checked for data updates on December 14, 2022.

**Selection of studies.** After a search of all databases, the retrieved records were sent to the EndNote Web® reference manager (Clarivate, London, UK) for duplicate detection. Two independent reviewers (A.L.A. and M.C.C.) assessed the title and abstract of each article and eliminated studies that did not meet the eligibility criteria. With these pre-selected studies, the full texts were read to analyze which studies exactly met the established criteria. Any differences were resolved with the help of a third reviewer (P.S.S.S.).

**Data collection and extracted data.** Study data were extracted using a standardized table, including the following information: author, year of publication, country, study design, study population (sex, age, diagnosis, associated factors, lesion size, and location), laser protocol (type, wavelength, and mean power), postoperative information (e.g., complications, symptomatology, and healing pattern), and main conclusions.

**Data summary.** To tabulate the collected information, a database with variables and categories was set up in a spreadsheet in Microsoft® Excel® for Microsoft 365 MSO (version 2211; Microsoft Corporation, Redmond, WA, USA). A narrative synthesis was carried out, organized around the characteristics of the researched population and the effectiveness of the applied treatment.

## RESULTS

**Research and selection of studies.** Initially, the databases revealed 266 studies. However, 35 articles were disregarded because they were duplicates and 209 were considered unrelated to the subject after reading the titles and abstracts. The remaining 22 studies were eligible for full-text analysis. Of these, 10 were eliminated after applying the inclusion and exclusion criteria. Finally, 12 studies (Al-Magro *et al.*, 2013; Pai Jagadish *et al.*, 2014; Bakhtiari *et al.*, 2015; Amaral *et al.*, 2017; Perales-Garza *Ret al.*, 2017; Andriola *et al.*, 2018; One & Uchôa, 2018; Mancera *et al.*, 2019; Otaibi & Al-Mohaya, 2020; Dhande *et al.*, 2021; Sawai *et al.*, 2021; Costa *et al.*, 2022) were included in the data extraction. Figure 1 provides a summary of the selection process.

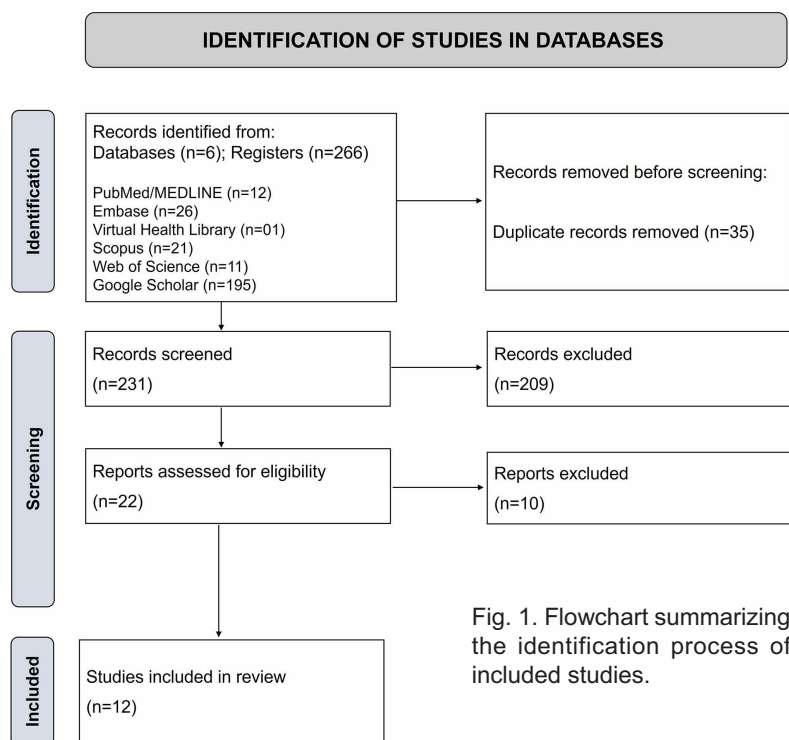


Fig. 1. Flowchart summarizing the identification process of included studies.

**Treatment employed.** In all cases, the diagnostic hypothesis of FFH or IFH was suggested and surgical removal indicated. The excisional biopsy was performed using a high-power diode laser, with a wavelength ranging from 808 to 960 nm, in continuous mode, and with an average power of 2830 mW (ranging from 500 mW to 5000 mW) (Table II). For removal, the lesions were tensioned with tweezers and completely excised from a uniform cut through its base. In only one case (Andriola *et al.*, 2017) it was necessary to carry out three sessions for the complete removal of the lesion, due to its great extension. One of the studies (Al-Otaibi & Al-Mohaya, 2020) reported minimal bleeding during the procedure, and in all others the absence of bleeding due to tissue coagulation was observed. Thus, in none of the cases was suturing necessary.

**General information of the included studies.** The general information collected from the included studies is presented in Table I. Of the 12 studies examined, 8 are case reports (Magro *et al.*, 2013; Bakhtiari *et al.*, 2015; Perales-Garza *Ret al.*, 2017; Andriola *et al.*, 2018; One & Uchôa, 2018; Mancera *et al.*, 2019; Dhande *et al.*, 2021; Costa, 2022) and 4 are case series (Al-Pai Jagadish *et al.*, 2014; Amaral *et al.*, 2017; Otaibi & Al-Mohaya, 2020; Sawai *et al.*, 2021). The studies were published from 2013 to 2022, with 5 Brazilian studies (Magro *et al.*, 2013; Amaral *et al.*, 2017; Andriola *et al.*, 2018; One & Uchôa, 2018; Costa, 2022), 3 Indians (Pai Jagadish *et al.*, 2014; Dhande *et al.*, 2021; Sawai *et al.*, 2021), 1 Iranian (Bakhtiari *et al.*, 2015), 1 Mexican (Perales-Garza *Ret al.*, 2017), 1 German (Mancera *et al.*, 2019), and 1 Saudi (Al-Otaibi & Al-Mohaya, 2020). The total sample comprised 64 patients, predominantly female (68.75 %, n=44) and mean age of 47.1 ( $\pm$ 16.1) years. In view of the diagnosis, there was a prevalence of FFH (79.68 %, n=51), followed by IFH (20.31 %, n=13). Possible causes were identified in 24 cases, with a greater association with the use of prostheses (n=17), followed by trauma (n=7). The average size of the lesions was 1.57 ( $\pm$ 1.05) cm, with a more frequent location in the buccal mucosa (32.81 %, n=21), tongue (29.68 %, n=19), and alveolar ridge (17.18 %, n=11) (Table I).

Surgical specimens were preserved in 10 % formaldehyde and sent for anatomopathological examination. Of the 64 cases studied, the diagnostic hypotheses of 13 cases of IFH and 51 cases of FFH were confirmed. In general, the microscopic sections of the IFH pieces revealed hyperplasia of the epithelial ridges and an inflammatory infiltrate of variable intensity. Those from FFH, on the other hand, showed dense bundles of collagen with fibroblasts and atrophy of the stratified squamous epithelium overlying crests due to proliferation of connective tissue. There were no interferences in the parts due to the use of the surgical laser, with minimal thermal damage in only one sample (Amaral *et al.*, 2017).

Regarding the postoperative period, all patients received guidance regarding hygiene and return in a period varying between two and ten days. Only one study (Amaral *et al.*, 2017) suggested the use of analgesics only in case of severe pain, having complained about mild, moderate, and severe pain in seven of the 15 patients. In addition, four patients also reported postoperative edema (Amaral *et al.*, 2017). The other studies prescribed analgesics without antibiotics. There were no reports of pain and swelling. In general, there were no interferences in the trans and postoperative periods and the healing of the

wounds occurred by second intention, with excellent evolution observed between seven and ten after the removal of the lesion. Complete healing took place between two and four weeks, without scar formation.

Table I. General information about the studies.

| Author, Year                       | Country      | Type of Study | Sample (n) | Sex                   | Age       | Diagnosis                | Associated Factors                  | Lesion Size (cm) | Lesion Location  |
|------------------------------------|--------------|---------------|------------|-----------------------|-----------|--------------------------|-------------------------------------|------------------|--|
| Magro <i>et al.</i> , 2013         | Brazil       | Case report   | 1          | M                     | 48        | FFH                      | Dental                              | 2,0              | Buccal Mucosa  |
| Pai Jagadish <i>et al.</i> , 2014  | India        | Case Series   | 3          | F                     | Mean 36.3 | FFH                      | Dental (n=1); N.R. (n=2).           | 1,6              | Buccal (n=1);<br>Gum (n=1);<br>Palate (n=1).                                       |
| Bakhtiari <i>et al.</i> , 2015     | Iran         | Case report   | 1          | F                     | 46        | FFH                      | Prosthesis                          | 3,5              | Tongue   |
| Amaral <i>et al.</i> , 2017        | Brazil       | Case Series   | 15         | F (n=12);<br>M (n=3)  | Mean 56.1 | IFH (n=10);<br>FFH (n=5) | Prosthesis                          | 3,3              | Alveolar Ridge (n=9);<br>Lips (n=3);<br>Buccal Mucosa (n=2);<br>Buccal Floor(n=1). |
| Andriola <i>et al.</i> , 2017      | Brazil       | Case report   | 1          | F                     | 55        | IFH                      | N.R.                                | N.R.             | Buccal Mucosa  |
| Perales-Garza <i>et al.</i> , 2017 | Mexico       | Case report   | 1          | M                     | 48        | FFH                      | Trauma                              | 0,5              | Tongue   |
| Lucena <i>et al.</i> , 2018        | Brazil       | Case report   | 1          | F                     | 65        | FFH                      | Dental                              | 1,0              | Tongue   |
| Mancera <i>et al.</i> , 2019       | Germany      | Case report   | 1          | M                     | 13        | FFH                      | Trauma                              | 1,3              | Buccal Mucosa  |
| Al-Otaibi <i>et al.</i> , 2020     | Saudi Arabia | Case Series   | 36         | F (n=25);<br>M (n=11) | Mean 43.7 | FFH                      | N.R.                                | 0,6              | Tongue (n=15);<br>Buccal Mucosa (n=15);<br>Labial Mucosa (n=6).                    |
| Dhande <i>et al.</i> , 2021        | India        | Case report   | 1          | M                     | 70        | IFH                      | Use of Nifedipine and residual root | 0,9              | Alveolar Ridge   |
| Sawai <i>et al.</i> , 2021         | India        | Case Series   | 2          | F (n=2);<br>M (n=1)   | Mean 23   | FFH                      | Trauma (n=1);<br>N.R. (n=1).        | 0,6              | Tongue (n=1);<br>Gum (n=1).  |
| Costa, 2022                        | Brazil       | Case report   | 1          | M                     | 61        | IFH                      | Prosthesis                          | 2,0              | Alveolar Ridge   |

M= Male; F= Female; FFH= Focal Fibrous Hyperplasia (FFH); IFH= Inflammatory Fibrous Hyperplasia (IFH); N.R.= Not reported.

Table II. Application of diode laser in procedures.

| Author, Year                       | Type of laser   | Wavelength (nm) | Power (mW) |
|------------------------------------|---|-----------------|------------|
| Magro <i>et al.</i> , 2013         | Diode laser Thera Lase Surgery (DMC LTDA)   | 808             | 4400       |
| Pai Jagadish <i>et al.</i> , 2014  | Diode laser unit (Picasso, AMD laser technologies, USA)                           | 810             | 1000       |
| Bakhtiari <i>et al.</i> , 2015     | Diode laser (Dr. Smile)   | 810             | 3000       |
| Amaral <i>et al.</i> , 2017        | Diode laser Thera Lase Surgery (DMC LTDA)   | 808             | 2960       |
| Andriola <i>et al.</i> , 2017      | Diode laser Thera Lase Surgery (DMC LTDA)   | 808             | 3.800      |
| Perales-Garza <i>et al.</i> , 2017 | Diode laser Aurora (Premier Laser Services, Inc., San Diego, CA, EUA)             | 810             | 500        |
| Lucena <i>et al.</i> , 2018        | Diode laser Thera Lase Surgery (DMC LTDA)   | 808             | 4000       |
| Mancera <i>et al.</i> , 2019       | Diode laser (Epic X, Biolase, EUA)  | 940             | 5000       |
| Al-Otaibi <i>et al.</i> , 2020     | Diode laser (Epic Biolase, Irvine, CA)  | 940             | 3500       |
| Dhande <i>et al.</i> , 2021        | Diode laser   | 810             | 2800       |
| Sawai <i>et al.</i> , 2021         | Diode laser (Photon Plus Dental Diode Laser, Zolar Tech e Mfg. Co. Inc, Alemanha) | 960             | 1000       |
| Costa, 2022                        | Diode laser Thera Lase Surgery (DMC LTDA)   | 880             | 2000       |

## DISCUSSION

Oral soft tissue injuries can be surgically treated with a scalpel, along with removal of the etiologic agent (Çayan *et al.*, 2019; Jesus *et al.*, 2020). However, several types of high-intensity lasers have recently been introduced for the treatment of oral lesions. Because they are readily absorbed by water and hemoglobin, soft tissue lasers can be used for incisions and hemostasis (Amaral *et al.*, 2017; Costa, 2022). In addition to those containing potassium-titanium-phosphorus (KTP), neodymium-yttrium-aluminium-garnet (Nd:YAG), and carbon dioxide (CO<sub>2</sub>), diode lasers with semiconductors also stand out (Costa, 2022). Its application results in three zones on the tissue: vaporization, necrosis, and coagulation. The size of these zones varies depending on the energy and focus of the application. In the presence of more energy, a larger vaporization zone is achieved and, consequently, a deeper incision (Magro *et al.*, 2013).

High-power lasers for soft tissue surgery have the benefit of stimulating healing and hemostasis, minimizing unpleasant symptoms and infections, reducing tissue contraction, eliminating the need for sutures, shortening surgical time, and reducing trauma, edema, and scarring (Magro *et al.*, 2013; Andriola *et al.*, 2017). Furthermore, diode lasers are compact, portable, efficient, and easy to use. Lesions can be removed by excision or vaporization, and the surgical wound formed by radiation is extremely superficial. When compared to typical surgical methods, inflammatory mediators are produced at lower levels, resulting in a reduced tissue reaction (Andriola *et al.*, 2017).

A disadvantage of these devices is the possibility of thermal tissue damage and, consequently, changes in the margins of the surgical specimen, which would make pathological analysis difficult (Angiero *et al.*, 2012; Azma & Safavi, 2013). However, the case reports and case series of the present review revealed that surgical specimens obtained with diode lasers were legible and undamaged. It is essential to note that the effects of lasers depend on the parameters used (wavelength, power, time and mode of emission, beam profile, and spot size) and thermal damage to tissue can be minimized if power, frequency, and duration of exposure are duly respected (Lopes-Santos *et al.*, 2022).

Amaral *et al.* (2015) evaluated the progression of 34 patients divided into control and study groups who had FFH removed using scalpel and diode laser,

respectively. According to their results, the study group did not demonstrate the need for suturing and had a shorter surgical time and greater edema, while the control group procedures involved suturing and greater use of analgesics. No significant differences were reported regarding pain, bleeding, and functional changes. Regarding the microscopic analysis, the study group showed a band of coagulation necrosis present on the lower edge of the pieces, but without any tissue damage, allowing adequate microscopic diagnosis.

Çayan *et al.* (2019), also performed a comparison between scalpel and diode laser procedures and determined that both were effective in treating IFH. However, variables such as improved hemostasis, absence of sutures and antibacterial efficiency may make the diode laser a more favorable option than scalpel surgery. Furthermore, no major tissue heat damage prevented proper microscopic evaluation of the specimens in this investigation and, again, postoperative pain did not reveal significant differences.

This review produced intriguing findings regarding the use of diode lasers in oral soft tissue surgery. However, some limitations should be mentioned. Case reports and case series are biased by definition. Furthermore, variations in clinical descriptions can have an impact on results. More research is needed to determine how different lesion configuration and size parameters affect the wound healing process following diode laser surgery.

---

**DO AMARAL, A. L.; CARNEIRO, M. C.; ALMEIDA, G. P.; DA SILVA SANTOS, P. S.** Tratamiento quirúrgico de la hiperplasia fibrosa oral con láser de diodo: una revisión integradora. *Int. J. Odontostomat.*, 17(2):136-141, 2023.

**RESUMEN:** El objetivo de este estudio fue realizar una revisión integradora sobre el uso del láser de diodo en el tratamiento de la hiperplasia fibrosa oral, con el fin de visualizar la eficacia quirúrgica, el patrón de cicatrización y el análisis de los principales resultados microscópicos. Se realizó una búsqueda sin restricciones de año e idioma en PubMed/MEDLINE, Embase, Virtual Health Library, Scopus, Web of Science y literatura gris. Se incluyeron reportes de casos y series de casos que brindaron información sobre pacientes diagnosticados con lesiones hiperplásicas orales tratados con láser de diodo, excluyendo aquellos a los que no se les había realizado análisis microscópico para confirmar el diagnóstico, así como aquellos que no brindaron información postoperatoria. Se incluyeron doce estudios (64 pacientes). Se observó prevalencia en el sexo femenino (68,75 %, n=44). Ante el diagnóstico, predominó la hiperplasia



fibrosa focal (79,68 %, n=51), seguida de la hiperplasia fibrosa inflamatoria (20,31 %, n=13). Para la remoción quirúrgica se utilizó un láser de diodo con una longitud de onda de 808 a 960 nm, en modo continuo, y una potencia promedio de 2830 mW. En general, no hubo interurrencias en el trans y postoperatorio y la cicatrización de la herida ocurrió por segunda intención, con excelente evolución. El uso de láseres de diodo de alta potencia puede ser una excelente alternativa terapéutica para las lesiones hiperplásicas orales. Se deben realizar más estudios clínicos a largo plazo para determinar los parámetros de ajuste del láser en diferentes lesiones orales.

**PALABRAS CLAVE: hiperplasia, diodo láser, terapia láser.**

## REFERENCES

- Al-Otaibi, L. M. & Al-Mohaya, M. A. Successful excision of oral irritational fibroma using 940 nm diode laser: case series. *J. Clin. Stud. Rev. Rep.*, 2(2):1-6, 2020.
- Amaral, M. B. F.; de Ávila, J. M. S.; Abreu, M. H. G. & Mesquita, R. A. Diode laser surgery versus scalpel surgery in the treatment of fibrous hyperplasia: a randomized clinical trial. *Int. J. Oral Maxillofac. Surg.*, 44(11):1383-9, 2015.
- Amaral, M. B.; Correia, L. F.; Noronha, M. S. & Mesquita, R. A. Diode LASER surgery in the treatment of fibrous hyperplasia: a prospective case series study. *Rev. Port. Estomatol. Med. Dent. Cir. Maxillofac.*, 58(1):52-7, 2017.
- Andriola, F.; Zanettini, L. M.; Marco, R.G.; Kunz, C.; Vaz, C. S. & Pagnoncelli, R. G. Diode laser in the surgical treatment of inflammatory fibrous hyperplasia: Case report and literature review. *Rev. Odontol. Cienc.*, 32(3):154-9, 2018.
- Angiero, F.; Parma, L.; Crippa, R. & Benedicenti, S. Diode laser (808 nm) applied to oral soft tissue lesions: a retrospective study to assess histopathological diagnosis and evaluate physical damage. *Lasers Med. Sci.*, 27(2):383-8, 2012.
- Azma, E. & Safavi, N. Diode laser application in soft tissue oral surgery. *J. Lasers Med. Sci.*, 4(4):206-11, 2013.
- Bakhtiari, S.; Taheri, J. B.; Sehhatpour, M.; Asnaashari, M. & Moghadam, S. A. Removal of an extra-large irritation fibroma with a combination of diode laser and scalpel. *J. Lasers Med. Sci.*, 6(4):182-4, 2015.
- Canger, E. M.; Celenk, P. & Kayipmaz, S. Denture-related hyperplasia: a clinical study of a Turkish population group. *Braz. Dent. J.*, 20(3):243-8, 2009.
- Çayan, T.; Erbasar, G. N.; Akca, G. & Kahraman, S. Comparative evaluation of diode laser and scalpel surgery in the treatment of inflammatory fibrous hyperplasia: a split-mouth study. *Photobiomodul. Photomed Laser Surg*, 37(2):91-8, 2019.
- Coluzzi, D. J. Fundamentals of lasers in dentistry: basic science, tissue interaction, and instrumentation. *J. Laser Dent.*, 16:4-10, 2008.
- Costa, M. L. *Biópsia Excisional de Hiperplasia Fibrosa Inflamatória com Laser de Diodo de Alta Potência: Relato de Caso*. Undergraduate Thesis. Maranhão, Universidade Federal do Maranhão, 2022.
- Derikvand, N.; Chinipardaz, Z.; Ghasemi, S. & Chiniforush, N. The versatility of 980 nm diode laser in dentistry: a case series. *J. Lasers Med. Sci.*, 7(3):205-8, 2016.
- Dhande, S. R.; Jabade, B.; Muglikar, S.; Ghodke, P.; Doshi, A. & Bhagwat, H. Diode laser for excisional biopsy of combined gingival enlargement: a case report. *The Dentist*, 1018(2):61-5, 2021.
- Jesus, A. O.; Matias, M. D.; Arruda, J. A.; Aires, A. V.; Gomes, I. P. & Souza, L. N. Diode laser surgery versus electrocautery in the treatment of inflammatory fibrous hyperplasia: a randomized double-blind clinical trial. *Clin. Oral Investig.*, 24(12):4325-34, 2020.
- Lopes-Santos, G., Santos, P. S. S. & Oliveira, D. T. Cytological artifacts mimicking vulgar pemphigus caused by diode laser surgery in oral lesion. *Int. J. Surg. Pathol.*, 2022. DOI: <https://www.doi.org/10.1177/10668969221143482>
- Magro, A. K.; Lauxen, J. R.; Santos, R.; Pauletii, R. N. & Magro, E. Laser cirúrgico no tratamento de hiperplasia fibrosa. *RFO*, 18(2):206-10, 2013.
- Mancera, I. C.; Escobar, F. E. & Llanos, L. S. Excision of a traumatic fibroma with diode laser in a pediatric patient: case report. *Rev. Fac. Odontol. Univ. Antioq.*, 31(1):162-70, 2019.
- Ogbureke, E. I.; Couey, M. A.; Vigneswaran, N. & Johnson, C. D. Large draining focal fibrous hyperplasia secondary to periapical granuloma. *Case Rep. Dent*, 2018:1-4, 2018.
- One, G. M. & Uchôa, R. C. *Odontologia: os Desafios do Mundo Contemporâneo*. João Pessoa, IMEA, 2018. pp.130-46.
- Pai Jagadish, B. S.; Padma, R.; Divya; Malagi, S.; Kamath, V.; Shridhar, A. & Mathews, A. Excision of fibroma with diode laser: A case series. *J. Dent. Lasers*, 8(1):34-8, 2014.
- Perales-Garza, R. V.; Sierra-Garcia, G. D; Nájera, R. I. & Perales-Perez, Á. V. Management of traumatic fibroma in a patient with cerebral palsy using 810nm diode laser. *J. Clin. Diagn. Res.*, 11(2):ZD01-ZD02, 2017.
- Santos, T. S.; Martins-Filho, P. R. S.; Piva, M. R. & Andrade, E. S. Focal fibrous hyperplasia: A review of 193 cases. *J. Oral Maxillofac. Pathol.*, 18(Suppl. 1):S86-9, 2014.
- Sawai, M. A.; Sharma, P.; Jafri, Z. & Sultan, N. Diode laser in the excision of intraoral fibroma: A safe tool for minimally invasive dentistry. *Indian J. Case Rep.*, 7(3):75-8, 2021.

Corresponding author:

Paulo Sérgio da Silva Santos  
Alameda Doutor Octávio Pinheiro Brisolla  
9-75, Bauru, SP  
Zip Code - 17012-901  
BRAZIL

E-mail: paulosss@fob.usp.br