

Crown-Root Angle Measurement in Permanent Central Incisors

Medición del Ángulo Corono Radicular en Incisivos Centrales Permanentes

Zuñiga Pamela & Albers Daniela

ZUÑIGA, P. & ALBERS D. Crown-root angle measurement in permanent central incisors. *Int. J. Odontostomat.*, 17(1):77-82, 2023.

ABSTRACT: The anatomical variations of teeth are directly related to the esthetics achieved in orthodontic treatment. These variations include the dental axes, such as the long crown axis and the long root axis. For this reason, these axes and the angle formed by their intersection, or crown-root angle, have been studied using several methodologies, mainly in central incisors. This study aimed to propose the visual- spatial processing as a method to determine the long crown axis and the long root axis, and thus measure the angle between these axes (crown-root angle) in the permanent upper and lower central incisors. The study had a quantitative, descriptive, observational and cross- sectional approach. The study sample consisted of 100 Cone-beam computed tomography (CBCT) images: 50 of permanent upper central incisors and 50 of permanent lower central incisors. The crown-root angle was measured considering the long crown axis and the long root axis. The mean crown root angle in the upper central incisors was 21.34° , with a standard deviation (SD) of 4.41° ; for the lower central incisors, the mean value was 20.05° with a SD of 4.18° . This study suggests that the visual-spatial processing can be a valid method to determine the long crown axis and the long root axis, also with the advantage of not requiring specific instruments and anatomical reference points, which simplifies the tracing of axes and thus measurement of the crown-root angle.

KEY WORDS: orthodontics, cone-beam computed tomography, visual-spatial processing.

INTRODUCTION

In the definition of orthodontic treatment, it is essential to consider the esthetic factor, since this is one of the main reasons for patient consultation. This has led researchers and clinicians to study the relationship between the anatomy and esthetics of teeth as treatment objective, with special attention to the central incisors, since they have greater exposure (Fredericks, 1974). Studies as those by Carlsson & Rönnerman (1973) and Mavroskoufis & Ritchie (1980) analyzed the anatomy of central incisors. The first analyzed the inclination of the buccal long crown axis, inclination of the long root axis and the angle between these axes; the second compared the mesiodistal diameter and crown length between different patients and in the same patient. Studies conducted by Fredericks (1974) and Okeson (2008) further related this anatomy to orthodontic treatment. While the first defined the treatment objective of esthetics based on

the inclination of tooth axes, the second indicated that the anatomy of central incisors has a direct implication in the active treatment phase and in its result, as well as in the retention phase.

This study recognizes the importance of considering the anatomical variables of central incisors during treatment and seeks a method that allows, in a simple manner, to determine the long crown axis, the long root axis, and the angle formed by these axes (or crown-root angle). It is relevant to consider this angle in the diagnosis, since it is directly related to the buccal surface, where the brackets are bonded in the straight arch technique. This was highlighted by Andrews (1989a), who established a relationship between the consistency of straight-wire treatment results with the consistency of crown-root angle values for central incisors.

Universidad Mayor, campus, Santiago, Chile.

Received: 2022-09-12

Accepted: 2022-11-25

Over time, several authors such as Taylor (1969), Carlsson & Rönnerman (1973), Fredericks (1974) and Andrews (1989b), among others, have proposed methods of varying complexity to measure the crown-root angle of central incisors. For example, Carlsson & Rönnerman (1973) used a stereograph to determine the long crown axis, and Fredericks (1974) conducted a previous study to determine the mean distance of the point of greatest crown convexity to trace the long crown axis.

However, the clinician is routinely able to visualize the crown and root inclination of incisors on a lateral radiographic image. This inherent capacity of the human eye is called visual-spatial processing, which allows identifying the position of a body, evaluating angles (Mandal *et al.*, 2012; Roselli, 2015) and estimating distances (Ortega *et al.*, 2014). The present study takes advantage of this ability to propose a simple method to determine the crown-root angle.

The objective of this study is to propose the visual-spatial processing as a method to determine the long crown axis and the long root axis, for measurement of the angle between these axes (crown-root angle) on the permanent upper and lower central incisors. For that purpose, Cone Beam Computed Tomography (CBCT) images were used, which allow controlling the over projection and distortion of anatomical structures that usually occurs in conventional radiographs (Adenwalla *et al.*, 1988; Arai *et al.*, 1999; Mah *et al.*, 2010).

MATERIAL AND METHOD

The study had a quantitative, descriptive, observational, and cross-sectional approach. The universe consisted of 214 maxillary and mandibular CBCT images recorded between 2014 and 2020 at the radiology center of the School of Dentistry of Universidad Mayor, Santiago, Chile. These records contained permanent upper and lower central incisors.

For sample size calculation, the criteria of the article "Calculation of the sample size in medical education research" were used, considering that there is not enough information on this aspect and that it is a preliminary study (García-García *et al.*, 2013). The sample size was 100 CBCT images: 50 of permanent upper central incisors (Annex 1) and 50 of permanent lower central incisors (Annex 2). Each image was obtained from a different patient, to avoid including homologous incisors that generally have similar anatomy.

The inclusion criteria were maxillary and mandibular CBCT showing erupted permanent central incisors, with complete apical formation and normal and undamaged anatomy. The exclusion criteria were patients with supernumerary teeth, cysts and/or tumors that might preclude measurement of the crown-root angle, permanent central incisors with sign(s) of dentoalveolar trauma, rhizolysis, crown and/or root fracture, restorations or fixed prostheses that might affect visualization of the long crown axis, dental tissue wear affecting more than the incisal third and carious lesions.

Data collection and analysis plan

Selection of CBCT. The 214 maxillary and mandibular CBCT images were obtained from the Planmeca Romexis® software database according to the aforementioned inclusion and exclusion criteria. Then, 100 CBCT images were randomly selected in Microsoft® Office 365® Excel: 50 of permanent upper central incisors and 50 of permanent lower incisors.

Calibration for determining the long crown axis and the long root axis. Calibration between examiners 1 and 2 (inter-examiner) consisted of plotting the crown-root angle axes on 30 sagittal CBCT images¹ of permanent central incisors (15 upper and 15 lower) using Microsoft® Office 365® PowerPoint software. Subsequently, examiner 1 measured the crown-root angle considering 2 decimals, using the AutoCAD® 2015 software (Annex 3). With these measurements, the calibration between examiners was determined using the Lin Concordance test and the Bland-Altman test, yielding a correct inter-examiner calibration with a Concordance Correlation Coefficient (CCC) of 0.914 and a confidence interval (CI) of 95% of Bland-Altman between -2.450 and 3.332, $p < 0.0001$ (Annex 4).

Before measuring the crown-root angle, examiner 1 underwent intra-examiner calibration, for which 30 permanent incisors², different from those used in the previous calibration, were selected. The angle was measured on 15 permanent upper central incisors and 15 permanent lower central incisors (Annex 5). These measurements were organized in a database using StataCorp (2015) statistical software Release 14, College Station, TX: StataCorp LP.; and were processed in the first instance by CCC, which retrieved a value of 0.995. Subsequently, the Bland-Altman test was performed, which determined a 95% CI between -0.303 and 0.499, $p < 0.0001$. Since data were concordant, an effective intra-examiner calibration was considered.

^{1,2} corresponding to CBCT images different from those included in the sample of 100 CBCT.

Standardization of images. Using the Planmeca Romexis® software, a section thickness of 1mm was achieved, and the most central in the three planes of space was selected. Thus, standardized CBCT images were obtained in the sagittal plane, which allowed tracing the long crown axis and the long root axis (Annex 6).

Protocol for tracing the axes of the crown-root angle based on visual-spatial processing. To facilitate the observation of axes, the image of the sagittal section of the upper central incisor was rotated using the “move/rotate volume” tool (Planmeca Romexis® software) until the palatal plane and the true horizontal line were parallel (Fig. 1 A).

Likewise, the image of the sagittal section of the lower central incisor was rotated until the long tooth axis formed an angle of 116° to 116.50° in relation to the true horizontal line (Fig. 1 B). These values were determined based on the fact that the mandibular plane angle has an average angulation of 26° in relation to the true horizontal line; in turn, the incisor presents an angle of 90° in relation to the mandibular plane. Thus, it can be stated that the lower central incisor, in relation to the true horizontal line, presents an average angulation of 116°.

All images were copied into a Microsoft® Office 365® PowerPoint file.

Subsequently, the following protocol was followed to trace the axes of the crown- root angle of the permanent upper and lower central incisors:

- The sagittal inclination of the long root axis was observed by visual-spatial processing.
- A straight line (yellow) was drawn in the buccal area close to the root surface, copying the inclination of the long root axis (Fig. 2).
- The sagittal inclination of the long crown axis was observed by visual-spatial processing.
- A straight line (yellow) was drawn in the buccal region close to the coronal surface, copying the inclination of the long crown axis (Fig. 3).
- After tracing both lines
- The line representing the long root axis (movement without inclination) was moved towards the root center.
- The line representing the long crown axis was moved until it contacted the previous line (movement without inclination).

- Both lines intersected forming an angle, which was named the crown-root angle (Fig. 4).

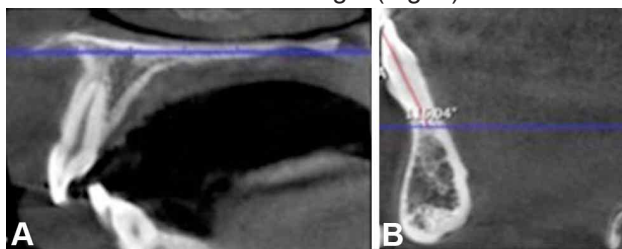


Fig. 1. Orientation and sagittal view of the upper and lower central incisor. A. Palatal plane parallel to the true horizontal line. B. 116° angle formed by intersection of the long axis of the lower central incisor with the true horizontal line.

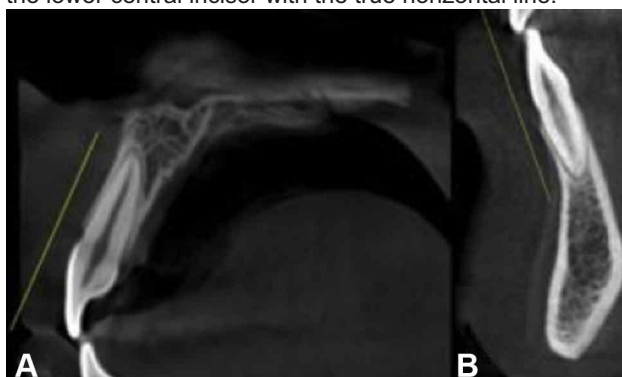

Fig. 2. Sagittal view of the upper and lower central incisor. Straight line representing inclination of the root surface: A. Upper central incisor. B. Lower central incisor.

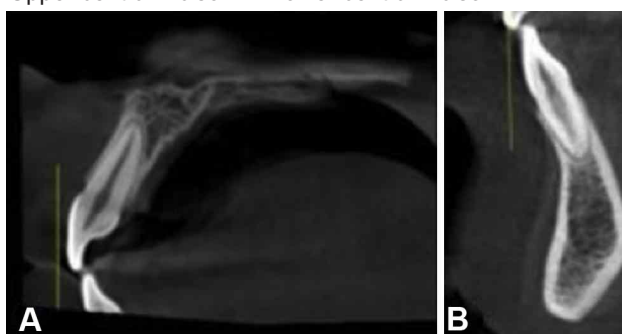


Fig. 3. Sagittal view of the upper and lower central incisor. Straight line representing the crown inclination: A. Permanent upper central incisor. B. Permanent lower central incisor.

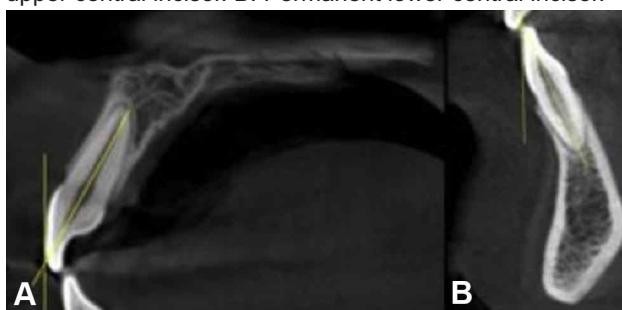


Fig. 4. Sagittal view of the permanent central incisors. A. Crown-root angle of the upper incisor. B. Crown-root angle of the lower incisor.

Then, the PowerPoint file that contained the images with traced axes was imported into the AutoCAD® 2015 software, for measurement of the crown-root angle.

Crown-root angle measurement protocol. The posterosuperior angle was measured on the upper central incisor (Figs. 5 A and B), and the posteroinferior angle was measured on the lower central incisor (Figs. 5 C and D). Two decimals were considered for both angles (Annex 7).

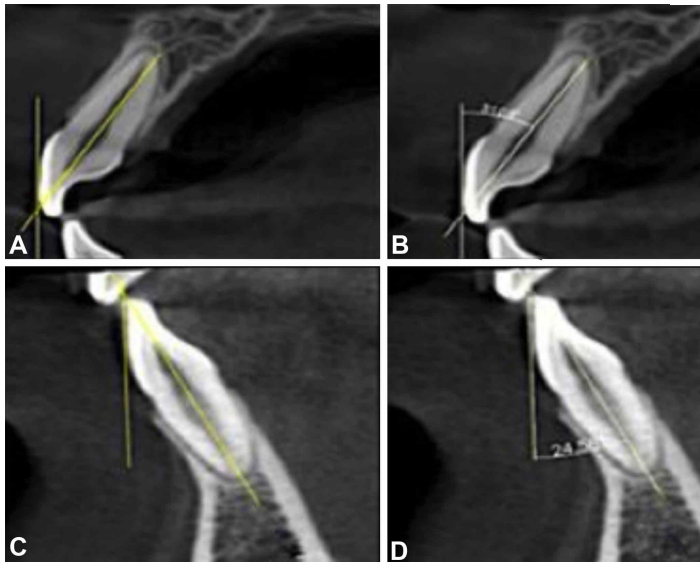


Fig. 5. Sagittal view of upper and lower central incisor in AutoCAD® 2015 software. A. Legs of the crown-root angle of the upper central incisor. B. Crown-root angle: 31.05° of the upper central incisor. C. Legs of the crown-root angle of the lower central incisor. D. Crown-root angle: 24.58° of the lower central incisor

RESULTS

From a universe of 214 CBCT of permanent central incisors, 100 met the inclusion and exclusion criteria (50 upper central incisor and 50 lower central incisor).

The angle measurements were organized in a database using the StataCorp software (2015) statistical software Release 14, College Station, TX: StataCorp LP., and processed by descriptive statistical analysis.

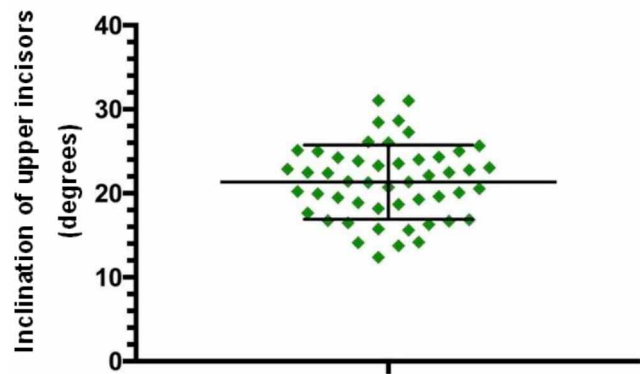


Fig. 6. Scatter plot of the crown-root angle with central tendency lines in permanent upper central incisors.

To determine the descriptive statistics to be used for both central tendency and dispersion, the Shapiro-Wilk test was performed, which revealed a normal distribution of data for the permanent upper central incisors (p=.866) and the permanent lower central incisors (p=.422).

Concerning the summarized measures of both groups, the upper incisors (Fig. 6) presented a slightly higher mean compared to the lower (Fig. 7), yet with similar SD between them (Table I).

The mean values, standard deviations and confidence intervals of the permanent upper and lower central incisors are shown in Table I.

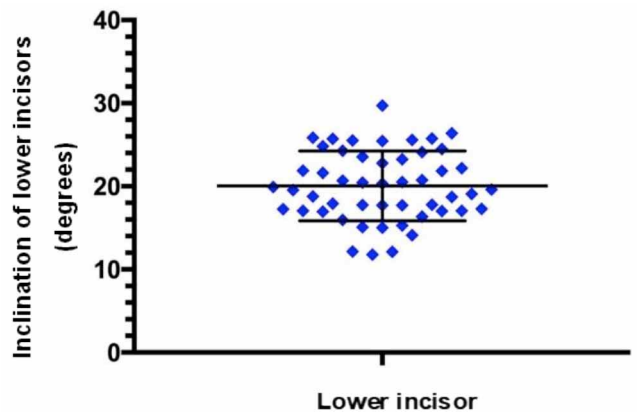


Fig. 7. Scatter plot of the crown-root angle with central tendency lines in permanent lower central incisors.

Table I. Descriptive statistics of the crown-root angle.

	N	Minimum	Maximum	Mean	SD	CI 95%
Upper incisors	50	12.4	31.05	21.34°	4.41°	20.12 - 22.56
Lower incisors	50	11.77	29.71	20.05°	4.18°	18.89 - 21.21

CI. confidence interval of 95 %.

DISCUSSION

The analysis of results allows the following discussion points: The existence of a large anatomical variability between the central incisors is confirmed, complicating the assignment of a single value to the crown-root angle. This is consistent with Carlsson & Rönnerman (1973), who concluded that the variation of this angle in the upper central incisor and that the variation of the sagittal location of the incisal edge in relation to the root are related to the different anatomical shapes of the incisor between individuals. It also agrees with Fredericks (1974), who analyzed 100 tracings of upper incisors and determined that this anatomical variation explained the different inclinations of the long crown axis and the longitudinal tooth axis between patients. Within the various implications of this anatomical variability in orthodontic therapy, Andrews (1989a) mentioned that, to use prescriptions options of straight wire brackets in different patients and to obtain similar final dental positions, it was fundamental to have low anatomical variability across the dental groups.

The crown-root angle has been assessed using multiple methodologies (Taylor, 1969; Carlsson & Rönnerman, 1973; Fredericks, 1974; Andrews, 198b), precluding the comparison between studies. However, there are methodological similarities between this study and that of Carlsson & Rönnerman (1973), allowing comparison of results. Both investigations obtained similar results for the angle between the long crown axis and the long root axis of the upper central incisor: the value of their study for this angle was 21.4° with SD of 4.2° . Additionally, another point of similarity between studies is the exclusion of the root apex point. This allows a more accurate copy the inclination of the long root axis, while simultaneously avoiding difficulties related to angle measurement due to the usual variations in the position of the root apex.

Notwithstanding, there is a central difference between this study and that of Carlsson & Rönnerman (1973), in the technique to determine the long crown axis. The present study did not include the stereograph used by these authors, but used the visual-spatial processing, thus simplifying the tracing of the long crown axis. A similar simplification is observed in the tracing of this axis and thus in the measurement of the crown-root angle, when compared with the methodology used by Fredericks (1974). This last study measures the angle between the long crown axis and

the long tooth axis, obtaining an average value for the upper incisor of 23.88° with a difference between the maximum and minimum values of 21° . Interestingly, to determine the inclination of the long crown axis, it uses the point of greatest crown convexity, which was located at 4.2 mm from the incisal edge towards the gingiva after a preliminary statistical study. However, it is complex to trace this inclination using this anatomical reference, since, as mentioned by the author, the curvature of the buccal surface varies widely between patients. This contrasts with the visual-spatial processing, which does not require exact location of these anatomical landmarks, thus simplifying the measurement process.

CONCLUSION

During the diagnostic and therapeutic stage, it is important to consider the inclination of the long axes of the crown and root, since they affect the results achieved using the same orthodontic straight wire therapy. This relationship between the inclination of the axes and the result of therapy is especially relevant in the central incisors since they are the teeth most exposed to evaluation by the patient.

This study suggests that the visual-spatial processing can be a valid method for determining the long crown axis and the long root, also having the advantage of not requiring specific instruments and anatomical reference points, which simplifies the tracing of axes and thus measurement of the crown-root angle.

Notwithstanding, it is suggested that the values obtained in this study, as well as the validity of the visual-spatial processing, should be analyzed in future studies on larger samples.

ZUÑIGA, P. & ALBERS, D. Medición del ángulo corono radicular en incisivos centrales permanentes. *Int. J. Odontostomat.*, 17(1):77-82, 2023.

RESUMEN: Las variaciones anatómicas de los dientes tienen directa relación con la estética lograda en el tratamiento de ortodoncia. Dentro de estas variaciones se encuentran los ejes dentarios, como el eje mayor de la corona y el eje mayor radicular. Por esta razón, se ha estudiado mediante diversas metodologías estos ejes y el ángulo formado por dicha intersección o ángulo corono radicular, principalmente en los incisivos centrales. El objetivo del presen-

te estudio es plantear la percepción viso espacial como método para determinar el eje mayor de la corona y el eje mayor radicular, y así medir el ángulo entre estos ejes (ángulo corono radicular) en los incisivos centrales superiores e inferiores definitivos. La investigación es de enfoque cuantitativo, descriptivo, observacional y transversal. La muestra del estudio fueron 100 imágenes de CBCT: 50 de incisivos centrales superiores definitivos y 50 de incisivos centrales inferiores definitivos. Se midió el ángulo corono radicular considerando el eje mayor de la corona y el eje mayor radicular. El promedio del ángulo corono radicular en los incisivos centrales superiores fue de 21.34° con desviación estándar (DS) de 4.41° y para los incisivos centrales inferiores se obtuvo como valor promedio 20.05° con DS de 4.18°. Este estudio plantea que la percepción viso espacial puede ser válido como método para determinar el eje mayor de la corona y el eje mayor radicular, teniendo además la ventaja de prescindir de instrumentos específicos y de puntos anatómicos de referencia, lo cual simplifica el trazado de los ejes y por ende la medición del ángulo corono radicular.

PALABRAS CLAVE: ortodoncia, tomografía computarizada de haz cónico, percepción viso espacial.

REFERENCES

- Adenwalla, S. T.; Kronman, J. H. & Attarzadeh, F. Porion and condyle as cephalometric landmarks--an error study. *Am. J. Orthod. Dentofacial Orthop.*, 94(5):411-5, 1988.
- Andrews, L. *Straight-Wire: the Concept and Appliance*. San Diego, K-W Publications, 1989a. pp.160-1.
- Andrews, L. *Straight-Wire: the Concept and Appliance*. San Diego, K-W Publications, 1989b. pp.181-2.
- Arai, Y.; Tammisalo, E.; Iwai, K.; Hashimoto, K. & Shinoda, K. Development of a compact computed tomographic apparatus for dental use. *Dentomaxillofac. Radiol.*, 28(4):245-8, 1999.
- Carlsson, R. & Rönnerman, A. Crown-root angles of upper central incisors. *Am. J. Orthod.*, 64(2):147-54, 1973.
- Fredericks, C. A method for determining the Maxillary Incisor Inclination. *Angle Orthod.*, 44(0):341-5, 1974.
- García-García, J. A.; Reding-Bernal, A. & López-Alvarenga, J. C. Cálculo del tamaño de la muestra en investigación en educación médica. *Investig. Educ. Med.*, 2(8):217-24, 2013.
- Mah, J. K.; Huang, J. C. & Choo, H. Practical applications of cone-beam computed tomography in orthodontics. *J. Am. Dent. Assoc.*, 141 Suppl. 3:7S-13S, 2010.
- Mandal, P. K.; Joshi, J. & Saharan, S. Visuospatial perception: an emerging biomarker for Alzheimer's disease. *J. Alzheimers Dis.*, 31 Suppl. 3:S117-35, 2012.
- Mavroskoufis, F. & Ritchie, G. M. Variation in size and form between left and right maxillary central incisor teeth. *J. Prosthet. Dent.*, 43(3):254-7, 1980.
- Okeson, J. P. *Management of Temporomandibular Disorders and Occlusion*. St. Louis, Elsevier/Mosby, 2008. pp.118-22.
- Ortega, G.; Alegreta, M.; Espinosa, A.; Ibarria, M.; Cañabate, P. & Mercè, B. Valoración de las funciones viso-perceptivas y visoespaciales en la práctica forense. *Rev. Esp. Med. Leg.*, 40(2):83-5, 2014.
- Roselli, M. Desarrollo neuropsicológico de las habilidades visoespaciales y visoconstruccionales. *Rev. Neuropsicol. Neuropsiquiatría Neurociencias*, 5:175-200, 2015.

Taylor, R. M. Variation in form of human teeth: I. An anthropologic and forensic study of maxillary incisors. *J. Dent. Res.*, 48(1):5-16, 1969.

Corresponding author:
Pamela Zuñiga
Universidad Mayor
Campus Santiago
Santiago
CHILE

E-mail: pameandrea.zunigagonzalez@gmail.com