

Biological Compatibility of the Endodontic Paste Prepared with Tetracycline, Thiamphenicol and Zinc Oxide Implanted on the Subcutaneous Tissue of Rats

Compatibilidad Biológica de Pasta Endodóntica Preparada con Tetraciclina, Tiamfenicol y Óxido de Zinc, Implantado en el Tejido Subcutáneo de Ratas

Elisabeth Cristina Gomes de Mattos^{*}; Marcelo Carvalho Chain[†];
Adair Roberto Soares dos Santos^{**}; Ricardo Tramonte^{***} & Rubens Rodrigues Filho^{*}

MATTOS, G. E. C.; CHAIN, C. M.; SANTOS, S. A. R.; TRAMONTE, R. & RODRIGUES FILHO, R. Biological compatibility of the endodontic paste prepared with tetracycline, thiamphenicol and zinc oxide implanted on the subcutaneous tissue of rats. *Int. J. Odontostomat.*, 2(1):7-16, 2008.

ABSTRACT: An important requirement for endodontic paste with antibiotics placed in direct contact with living tissues is biocompatibility. The aim of this study was to evaluate the paste biocompatibility prepared with zinc oxide (1.25mg), tetracycline (8mg) and thiamphenicol (26.67mg). The paste and its components were implanted separately through polyethylene sterile tubes of 10mm in length and 1.3mm in diameter, in the subcutaneous tissue of rats with the experiment control at intervals of 3, 7, 15 and 30 days. Each day 6 rats were used, being 3 of them with implant of the substances in four sites placed on the back of the animals and 3 sham animals where it was implanted the polyethylene empty tubes. The experimental animals were anesthetized in an intra-peritoneal way with ketamina and xilazina (0.75ml / g body weight). After the experimental periods, the animals were anesthetized with the same anesthetic overdose. It was held an excision biopsy of the implant area with 10 mm to the security limit included in paraffin following a plan of random histological cut and uniformly isotropic or oriented cuts according to stereological principles, getting a statistical estimative of the relative amount of inflammatory cells or not on the test system, getting as a result the paste biocompatibility, being the zinc oxide the most toxic element for the cell quality found.

KEY WORDS: biocompatibility, tetracycline, antibiotic paste.

INTRODUCTION

Although, the ethical treatment concept of patients comes since Hippocrates' age, the idea that new dental material must be tested safely and efficiently before clinical use it is much more recent (Anusavice, 2005). The biocompatibility is defined as the ability of a material exerting specific functions when applied in contact with living tissue of a particular host, without, however, causing damage or harm to them (Estrela, 2005).

Thus, before inserting a material to replace a lost tissue, it is needed to know the structure and function of this tissue as well as the material properties (Estrela). Many studies have been held to assess the

tissue response to the dental materials. Takahashi *et al.* (2007), analyzed the rat tissue responses of Guedes Pinto's paste and calcium hydroxide. Guedes Pinto's paste caused small swelling and provided less influence on the repairing process. Oliveira & Zamperini (2007), in a biological assessment in connective tissues of rats, the dental materials used for pulpal protection verified that all materials were irritating to the connective tissue in the early periods and Hydical presented better biological results.

The antibiotics combination to dental materials has began in 1960's when Shay (1960) analyzed the use of antibiotics for pulpal vitality conservation.

^{*} Department of Stomatology, Universidad de Santa Catarina, Brazil.

^{**} Department of Physiology, Universidad de Santa Catarina, Brazil.

^{***} Department of Morphological Sciences, Universidad de Santa Catarina, Florianopolis, SC, Brazil.

Moreover, Perdiza in 1964 evaluated the zinc oxide combination to cloramphenicol as filling pastes of root canals and Cappiello (1964), evaluated different possibilities of achieving the endodontic treatment in immature teeth, including the use of a paste based on antibiotics.

It is known that remaining bacteria in the root canals system are a significant factor in the endodontic therapy failure (Melker *et al.*, 2006), being the anaerobic gender strict to *Fusobacterium*, *Prevotella*, and *Phorphiromas* which are prevailing in pulpal and periapical infections (Tronstad *et al.*, 1990; Baugartner *et al.*, 1991; Vigil *et al.*, 1997; De Deus, 2002; Sunde *et al.*, 2002, Desai *et al.*, 2004). Besides, the anaerobic bacteria can be also found fungal species on the endodontic injury (da Silva *et al.*, 2000). These microorganisms when they reach more internal dental areas become inaccessible to the biomechanical preparation, remaining in this way on the root canals system after the endodontic treatment. Windley *et al.* (2005) have recently tested in vivo and in vitro a paste composed by antimicrobial ciprofloxacin, metronidazole and minocycline and obtained the pathogenic microorganisms removal commonly present in infected root canals. In addition, Barja-Fidalgo *et al.* (2007) analyzed the antimicrobial action in vitro of 5 pastes used in the endodontic treatment of immature teeth, being the pastes CTZ and 3 Mix composed of antibiotics which had better results.

Amorim *et al.* (2006) compared three pediatric pastes with antibiotics in its composition and concluded that especially in pediatric dentistry, the difficulties found in the antimicrobial control requires the use of filling pastes of root canals with broad antimicrobial activity.

On the 1960's, Cappiello developed a cement based on antibiotics, zinc oxide and Eugenol, and since then it has being adopted at Londrina State University for immature teeth pulpotomies treatment with very favorable results (Walther, 1965). Souza *et al.* (2005) studied the paste biocompatibility of Cappiello that contains Eugenol in its composition, having as control the zinc oxide paste and Eugenol implanting the substances that were contained in polyethylene tubes of 10 mm in two shops on the back of the rats. Ajimura *et al.* (2003) repeated the study removing the Eugenol from the paste original formula and observed high toxicity of the endodontic paste with antibiotics when compared with zinc oxide and Eugenol cement.

The paste biocompatibility evaluation used on the researches by Ajimura and Souza *et al.* was performed 3, 7, 15, 30, 60 days after the paste implantation. It is being recommended that in a short term of evaluation (two days) it is important to determine the incision effects and the surgical procedure. For a period of seven days it was evaluated the rationale table evolution, and for 14, 30 and 60 days it was determined the comparative way of the rationale pattern for each material in test that signalizes likely the repairing mechanism for longer periods of time.

As among many papers published about the use of endodontic paste, containing antibiotics in its composition it is observed much controversy, the goal of this research was to evaluate the paste biocompatibility composed of zinc oxide, tetracycline and thiamphenicol, analyzing also separately their components to identify the existence of some toxic component since the paste clinical efficiency was proven at Londrina State University.

MATERIAL AND METHOD

Endodontic paste standardization: For the paste amount standardization to be implanted in animals it was set that it would be the amount placed in the chamber of immature molar pulpal teeth which correspond to 0.365 g. The paste was prepared with 8 mg of tetracycline (Bristol-Myers Squibb), 26.67mg of thiamphenicol (Zamboni) and 1.25 mg of zinc oxide (Biodinâmico) that were mixed to obtain a dental pulp consistency.

Animals: It was used 24 Wistar rats, with 200 to 300 gr divided into 4 experimental groups with 6 animals in each of them, being 3 operated and 3 sham. Each group of animals was analyzed for 3, 7, 15 and 30 days. This present work was approved by the CEUA – UFSC (number PP00095).

Surgical procedure for endodontic paste implantation and its components: Every surgical procedure was held using aseptic technique, under deep anesthesia, induced by i.p. injection of ketamina and xilazina (0.75 ml/g body weight). In a determined place was held an incision of 18 mm long and 08 mm in depth. The experimental materials in the form of powder, (tetracycline and zinc oxide) were dissolved in a neutral environment, and thiamphenicol (gel) was placed in tubes with the use of insulin sterile syringes.

To avoid spreading one of the tube ends it has been closed to heat. With forceps aid, the polyethylene tubes containing the endodontic paste, and its components separately were implanted on the back of the animals according to the sequence represented in Fig. 1. In sham animals only the tubes were implanted. Each polyethylene tube, 10 mm long and 1.3mm in diameter, was placed in parallel to the incision with the opening directed to the head of the animal. Afterwards, the tissue was repositioned and sutured skin with suture wire of 3.0. After the experimental periods, the animals were sacrificed with overdose of the same anesthetic, and excision biopsy of the area of the implanted tubes was held.

Histological and morphometrical analysis of the subcutaneous tissue: Paper discs, compatible with the biopsy size were used to facilitate the tissue fixation in formaldehyde solution to 10% buffered. After 48 hours of fixation, the surgical pieces were sectioned from the tube opening tip of the polyethylene implanted, extending up to 10 mm (security limit) and then included in paraffin following a cutting plan (Fig. 2), obtaining – random histological cuts and uniformly isotropic (URL), or rather, oriented cuts (Mattfeldt *et al.*, 1986), according to the stereological principles to obtain a statistical estimative of the relative amount of cells in the test system, since it was analyzed in this way the cells in the whole histological volume cuts.

This methodology allows the area calculation and the connective tissue volume to be in contact with the endodontic paste or with each of its components. In this present study it is analyzed the connective tissue reaction area measured in mm from the polyethylene tube implanted with the substances on the back of the animals, employing Cavallieri principle, for the volume calculation in URL cuts (Mandarim-de-Lacerda, 2003). Thus, the two pieces obtained were included in paraffin and submitted to microtome. It was obtained 5 cuts of 5 µm thick semi-serialized (spacing 500/500 mm) from each of the 2 pieces. The cuts semi-serialized were made until disappearing all the traces of the possible tissue

reactions caused by material contained in the tube. It was obtained 83 blades with a total of 415 histological cuts.

The histological cuts were stained by hematoxylin and eosin (HE) and analyzed at Optical Microscope Nikkon Labphot II, with an eye grid, previously calibrated with a "bladed object" to indicate the Micrometric coefficient of each of the objective used for measuring the inflammatory reaction and the number of cells present in specific areas in the subcutaneous connective tissue of these animals, according to the method advocated by Mandarin-de-Lacerda (2003), for stereological analysis.

To hold a morphometric analysis and the calculation of the analyzed area of the inflammatory reaction was used a System-Test (Briarty, 1975), square composed by lines, previously calibrated with blade-object, with objective of 4x, with total area of 3.2mm x 1.8mm.

To calculate the number of polymorphonuclear and mononuclear present in the connective tissue located in front of the polyethylene tube it was used the same system-Test previously calibrated with objective of 100x, whose total area corresponds to 130 microns in length by 92 microns width. It was analyzed 5 random areas located in the connective tissue that presented or not inflammatory reaction to the paste or their components (Almeida & Souza, 2003).

The following histological events were evaluated in these areas: inflammatory reaction, rationale breadth area with the tube opening, polymorphonuclear and mononuclear presence and quality.

RESULTS

The zinc oxide in the first week did not induce significant inflammatory reaction, which was restricted to an area of 1.34mm in length for three days and of 2.14mm to the 7 days from the tube implanted in the

Table I. Calculation of mononuclear and polymorphonuclear cells in the "field-test" found by substance on the subcutaneous connective tissue of rats in 5 blades analyzed 3, 7, 15 and 30 days after the paste implantation or their components. M- mononuclear; P-polymorphonuclear.

Cels Components	3 M	3 P	7 M	7 P	15 M	15 P	30 M	30 P
Zinc oxide	6	4	5	3	32	10	64	11
Tianphenicol	1	0	0	0	4	0	3	0
Tetracycline	9	2	7	0	17	1	5	0
Paste	4	6	6	0	2	0	0	0

Table II. The inflammatory reaction extension measurement (mm) caused on the subcutaneous connective tissue of rats, 3, 7, 15 and 30 days after endodontic paste implantation or their components. The data are expressed as the average of 5 calculation areas, obtaining the density of cells in the test system in relation to the space analyzed.

Days	3	7	15	30
Components				
Zinc oxide	1.34	2.14	5.24	5.96
Tiamphenicol	1.86	0.00	0.46	0.20
Tetracycline	4.18	5.32	1.46	2.44
Paste	1.12	2.52	3.30	0.00

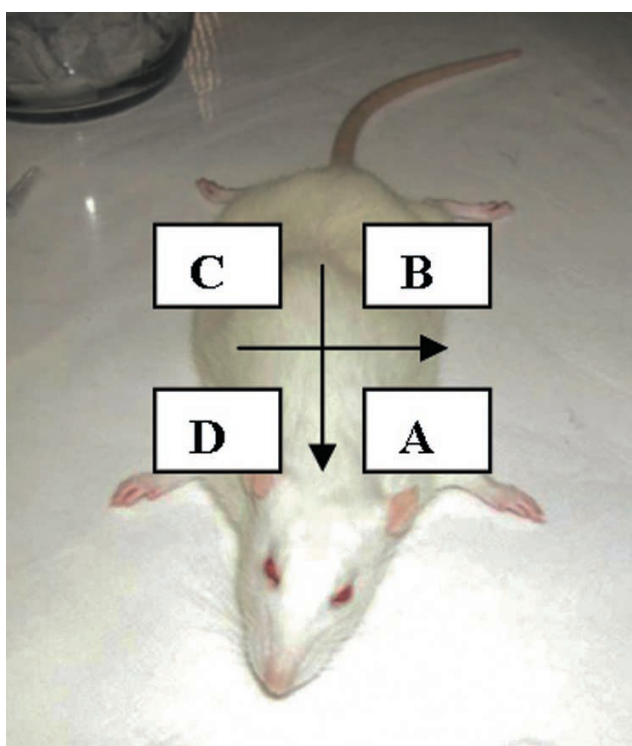


Fig. 1. Schematic representation of the surgical sites where the polyethylene tubes were implanted containing paste (A), zinc oxide (B), thiamphenicol (C), tetracycline (D).

connective tissue of rats (Table II). In fifteen days it was observed a large increase in mononuclear and some polymorphonuclear reporting increased inflammatory reaction in an area of 5.24mm long (Tables I and II). It was noticed in thirty days a large increase in the quantity of mononuclear just expressing an inflammatory reaction around 5.96mm in length from the opening of a polyethylene tube (Tables I and II; Fig. 3).

The thiamphenicol did not cause actually any inflammatory reaction in the subcutaneous connective

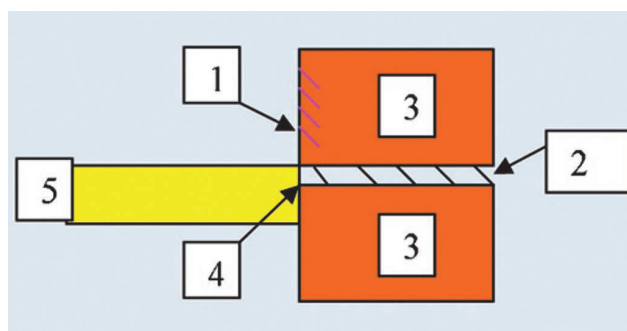


Fig. 2. The cutting schematic representation realized in the rat skin indicating the inclusion face in paraffin for manufacturing the blades used for quantifying the tissue reactions caused by endodontic paste or its components implanted in animals; (1) inclusion face A, (2) inclusion face B, (3) biopsy, (4) chamber area, (5) polyethylene tube.

tissue of rats in the first week (Table I). After fifteen days it was observed a discrete reaction measuring approximately 0.46mm along the pieces, with the presence of a few mononuclear, which is extended for 30 days indicating a character reaction more immune than fagocitary characterizing a chronic reaction (Table 2).

The tetracycline induced an inflammatory reaction with predominance of mononuclear three seven days after its implantation (tables 1 and 2) with a length of 4.18 mm and 5.32mm, respectively, from polyethylene tube. The inflammatory reaction continues, however, chronically with an average of 2 mm along the pieces with many mononuclear at 15 days (Table 2; Fig.4).

The paste caused an inflammatory reaction with polymorphonuclear predominance three days after its implantation, but encapsulated and limited to the first cut along with the implanted tube in an area of 1.12mm in length. At 7 days, on the five areas examined, it was observed a connective tissue reaction with a mean extension of 2.52mm, in which only mononuclear was

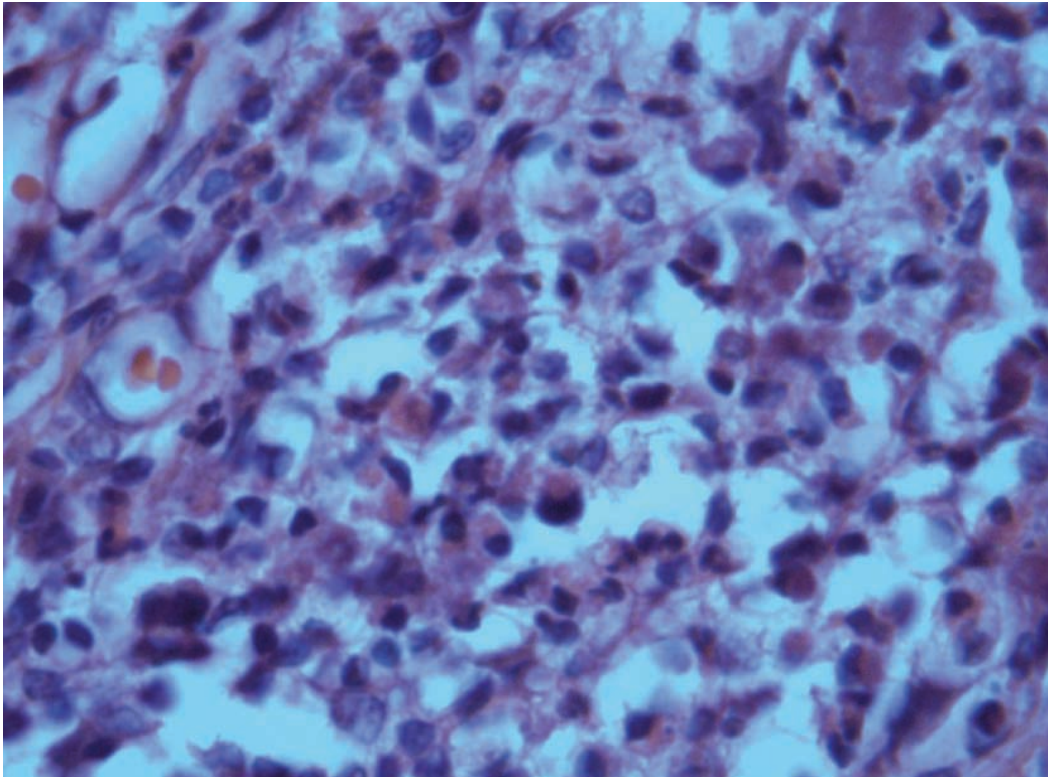


Fig. 3. Photomicrograph demonstrating the presence of polymorphonuclears in the subcutaneous connective tissue of rats thirty days after the zinc oxide implant (objective de100X, HE staining).

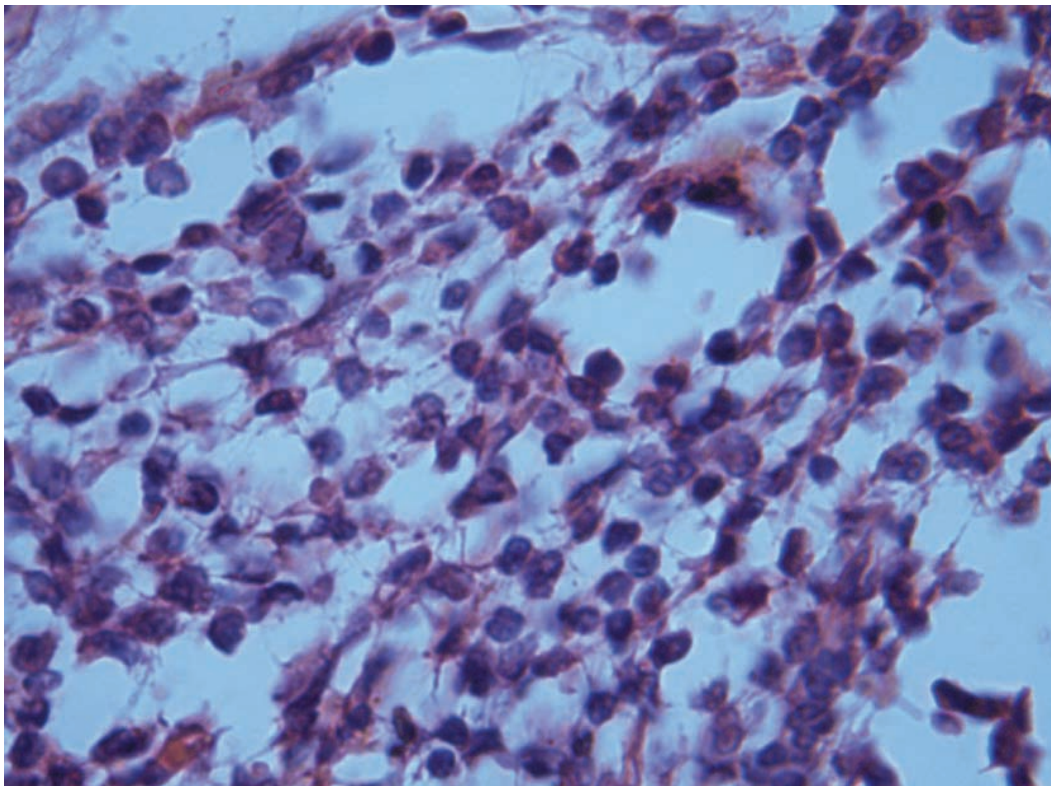


Fig. 4. Photomicrograph showing the presence of a large number of mononuclears in the subcutaneous connective tissue of rats 15 days after the tetracycline implantation (objective 100X; HE staining).

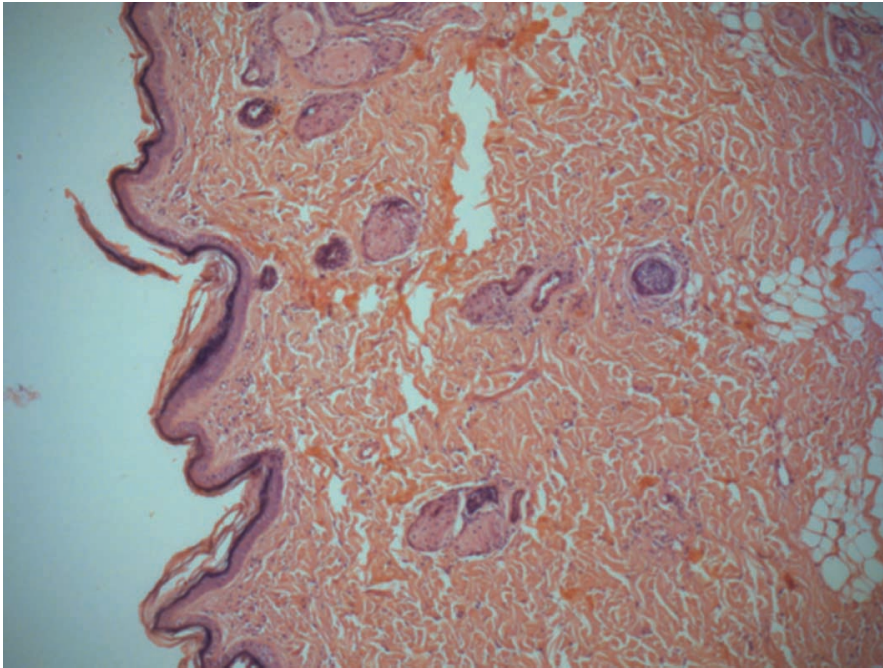


Fig. 5: Photomicrograph demonstrating the absence of inflammatory reaction in the subcutaneous connective tissue of rats 30 days after the endodontic paste implantation (objective 10X; HE staining)

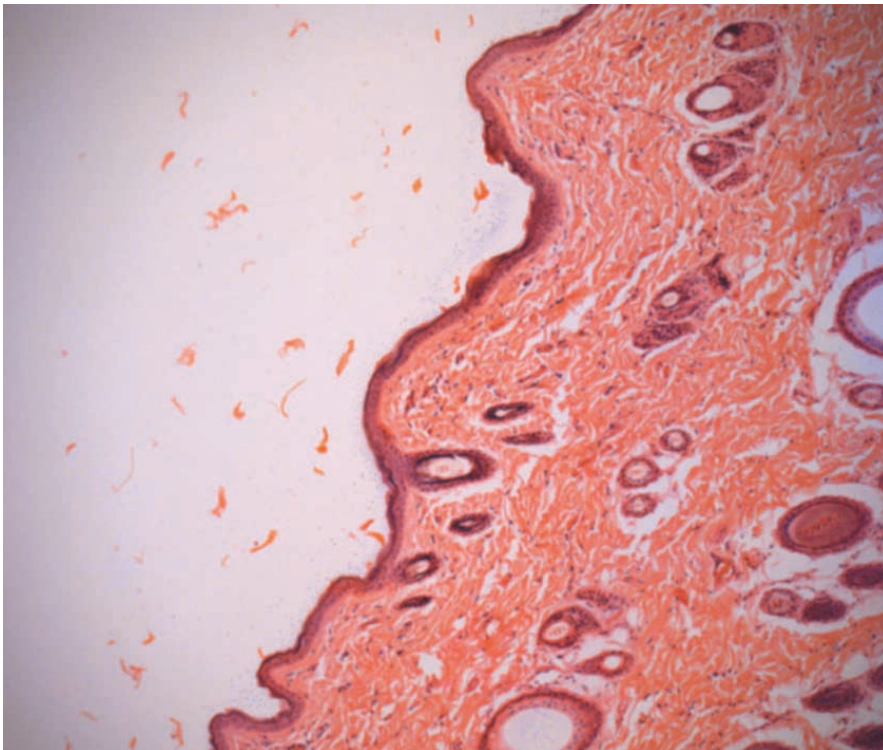


Fig. 6: Photomicrograph demonstrating the absence of inflammatory reaction in the subcutaneous connective tissue of sham rats, 15 days after polyethylene implantation tube (objective 10X; HE staining).

present (Tables I and II). The inflammatory reaction after 15 days it was qualitatively, chronically small and a mean extension of 3.3mm from the tube (Tables I and II). Thirty days after the endodontic paste implantation, no inflammatory reaction was observed in the tissue (Tables I and II; Fig.5). In sham animals, which had only implant of the polyethylene sterile tube, were noticed normal connective tissue with few cells, summarized in fibroblasts and intercellular substances, demonstrating that the tube did not affect the animal connective tissue (Fig.6).

DISCUSSION

The biocompatibility definition says that a material to be biocompatible must exert specific functions when in contact with living tissue of a host, without, however, causing damage or harm to it (Estrela).

In the present study, it is analyzed the possibility of endodontic paste consisted of tetracycline, thiamphenicol and zinc oxide to be biocompatible. Thus, the paste and its constituents were implanted in the subcutaneous tissue of rats and the appearing or not of tissue reaction were evaluated 3, 7, 15 and 30 days after the implantation. The results obtained indicate that the paste studied induces to inflammatory reaction of low intensity, mainly fifteen days after its implantation and any reaction thirty days later, which suggests being the paste biocompatible with the living tissue.

In connective tissue can be seen different cell types as plasmocytes, lymphocytes, monocytes and macrophages (mononuclear cells) getting into the organism defense and repairing process that appear in the chronic inflammatory process. On the other hand, the acute inflammation predominance is the polymorphonuclear cells such as lymphocytes and eosinophils (Junqueira & Carneiro, 2003). Meanwhile, Guidugli-Neto (1997) showed that to assure to be the polymorphonuclear typical of acute inflammation and mononuclear of chronic inflammation is most of time too academic, because in some situations as in suppurative osteomyelitis (chronic) predominates neutrophils and viral infections (acute), mononuclear presence (Junqueira & Carneiro). This study did not have the purpose to identify the cell types, but its presence characterizing the inflammation type.

The zinc oxide when applied alone showed to be the most toxic paste component, mainly 15 and 30 days after its implementation, which can be confirmed by the inflammatory reaction extent and the cell types present in large amount (polymorphonuclear). The results show and extend other results as those obtained by Koulaouzidou *et al.* (2005) that was shown to be the most cytotoxic zinc oxide. This irritating potential can be caused by the lack of Eugenol on the paste composition, because Costa *et al.* (1994) showed that the zinc oxide and Eugenol paste induce to an inflammatory reaction with mononuclear predominance in thirty days after its implantation. Kielbassa *et al.* (2007) stated that the paste consisted of zinc oxide and Eugenol induced the formation of a fibrous capsule that prevents the re-absorption. Moreover, other works have shown the therapeutic effect of Eugenol in the dental pulp connective tissue (Watts & Paterson, 1987; Sübay *et al.*, 2000).

The thiamphenicol is a broad antifungal spectrum, derived from the chloramphenicol, which acts on the gram-positive and gram-negative microorganisms, acting by inhibiting bacterial protein synthesis (Shilb *et al.*, 1995). When evaluated separately the thiamphenicol induced a discreet inflammatory reaction in the connective tissue, only from the second week and which extended until 30 days after its implantation, but chronic, demonstrating to be thiamphenicol a medicine with little irritating potential on the connective tissue.

Another important factor on the researches about the endodontic paste is tetracycline, which is linked in different levels to plasma proteins, forming complexes

with calcium. (Man Chin & Ferreira, 1995) Thus, tetracycline is deposited along with calcium during the bone, dentin and cement calcification. The paste constitution is due to the fact of being active against gram-positive and gram-negative micro-organism, anaerobic bacteria, facultative anaerobic and spirochetes, which are part of the pulpal and periapical infections (Windley *et al.*).

Besides, the tetracycline influences the bone tissue regeneration, including the chemiotatic effect to osteoblasts and anticollagenolytic activity (Man Chin & Ferreira), which contributes significantly to the new bone formation demonstrating that the tetracycline has biological compatibility. The results obtained in the present study showed that this antimicrobial was able to induce inflammatory reaction in the connective tissue of rats that had its highest intensity 15 days after the implantation; however, with a mononuclear predominance suggesting to be a chronic inflammatory process.

All these components when associated originate a paste that was capable of inducing, 3 and 7 days after its implantation, an acute inflammatory reaction, however, restricted (1.12mm in average), with mononuclear predominance. Later there was a qualitative regression of cells and after thirty days it was not observed inflammatory reaction. Based on the results obtained in this present study, it is inferred the hypothesis that the inflammatory reaction caused by paste composed by thiamphenicol, tetracycline and zinc oxide is very small and it can characterize the biocompatibility of it to the connective cavity filling tissue. Working with materials for covering the cavities, Oliveira *et al.* (1997), concluded that the materials are biologically acceptable, when in contact with the subcutaneous connective tissue of rats, occurs repairing in the area during the experiments. When the reaction is considered small it can be said that the material used is biocompatible.

Costa *et al.* (1996) concluded that the zinc oxide and Eugenol present acceptable biocompatibility as it was observed a reaction with an area of 0.347 mm sixty days after its utilization. Moreover, Minarelli & Roslindo (2003), concluded from the experiments held with prime bond that it is biocompatible after observing the histological event regression.

From the results obtained, it is needed to continue the biocompatibility tests of the referred paste, now applying to the material in test on the teeth of animals

that have these structures similar to the human beings.

The paste consisted of thiamphenicol, tetracycline and zinc oxide can be considered

biocompatible due to the area limitation and the quality of inflammatory cells found, being the zinc oxide alone the most irritating element of its composition due to the polymorphonuclear presence still after 30 days.

MATTOS, G. E. C.; CHAIN, C. M.; SANTOS, S. A. R.; TRAMONTE, R. & RODRIGUES FILHO, R. Compatibilidade biológica de la pasta endodóntica preparada con tetraciclina, tiamfenicol y óxido de zinc, implantado en el tejido subcutáneo de ratas. *Int. J. Odontostomat.*, 2(1):7-16, 2008.

RESUMEN: Un requisito importante para la pasta endodóntica preparada con antibióticos, que es colocada en contacto directo con los tejidos vivos es la biocompatibilidad. El objetivo de este estudio fue evaluar la biocompatibilidad de la pasta preparada con óxido del zinc (1,25mg), tetraciclina (8mg) y el tiamfenicol (26,67mg). La pasta y sus componentes fueron implantados por separado a través de tubos estériles de polietileno de 10 mm de longitud y de 1,3mm de diámetro en el tejido subcutáneo de ratas en intervalos de 3, 7, 15 y 30 días. Cada día, 6 ratas fueron implantadas en cuatro sitios ubicados en la parte posterior de los animales, 3 de ellas con el implante de las sustancias y 3 fueron implantados con los tubos de polietileno vacíos. Los animales del experimento fueron anestesiados intraperitonealmente, con ketamina y xilasina (0,75 ml/g peso corporal). Después de los periodos experimentales, los animales fueron anestesiados con la misma sobredosis anestésica. Fue realizada una biopsia exisional del área del implante con 10 mm de límite de seguridad, luego se realizaron cortes histológico al azar uniformemente isotrópicos o orientados según los principios esteriológicos, consiguiendo un estimativo estadístico de la cantidad relativa de células inflamatorias en el sistema de prueba. Se obtuvieron resultados de la biocompatibilidad de la pasta, siendo el óxido del zinc el elemento mas tóxico según la cualidad de las células que fueron encontradas.

PALABRAS CLAVE: biocompatibilidad, tetraciclina, pasta antibiótica.

REFERENCES

- Ajimura, K. T.; Ferelle, A. & Akatsu, T. *Estudo comparativo da biocompatibilidade de um cimento à base de antibióticos contendo Tiamfenicol, Tetraciclina e Óxido de Zinco com o Cimento de Óxido de Zinco e Eugenol, em tecido subcutâneo de rato.* In: III Congresso Mundial de Odontologia. Anais do III Congresso Mundial de Odontología, Londrina, 2003. p. 40.
- Almeida, R. J. & Souza, C. J. A. S. *Biocompatibilidade de Materiais endodônticos em Odontopediatria: Avaliação histológica da resposta inflamatória, por meio de implantes intra-ósseo em cobaias guinea-pig.* Tesis Maestrado em Endodontia. Faculdade de Odontología de Universidad Federal de Uberlandia, 2003. p22.
- Amorim, L. F. G.; Toledo, O. A.; Estrela, C. R. A.; Decurcio, D. A. & Estrela, C. Antimicrobial analysis of different root canal fillings pastes used in pediatric dentistry by two experimental methods. *Braz. Dent. J.*, 17:317-322, 2006.
- Anusavice, K. J. *Materiais Dentários Philips.* 11^a ed. Rio de Janeiro, Elsevier, 2005. pp.162-189.
- Baumgartner, J. C. & Falkler, W. A. Jr. Bacteria in the apical 5 mm of infected root canals. *J. Endod.*, 17:380-3, 1991.
- Barja-Fidalgo, F.; Hirata-Junior R. & Oliveira, B. H. Avaliação da ação antimicrobiana in vitro de 5 pastas utilizadas no tratamento endodôntico de dentes decíduos. *Braz. Oral Res.*, 21:311, 2007.
- Briarty, L. G. Stereology: methods for quantitative light and electron microscopy. *Sci. Prog.*, 62(245):1-32, 1975.
- Cappiello, J. Nuevos enfoques en odontologia infantil. *Rev. Circ. Odontol. Rosario*, 52:138-45, 1964.
- Costa, C. A. S.; Benatti Neto, C.; Abdalla, R. E.; Gonzaga, H. F. S. & Lia, R. C. C. Costa CAS, Benatti Neto C.; Abdalla, R. E.; Gonzaga, H. F. S. & Lia R. C. C. Estudo preliminar da compatibilidade biológica de um cimento à base de antibiótico e óxido de zinco e eugenol quando implantado em tecido subcutâneo de rato. *Rev. Odontol. Univ. São Paulo*, 8:65-70, 1994.

- Costa, C. A. S.; Hebling, I. & Teixeira, M. F. Compatibilidade biológica do tecido conjuntivo subcutâneo de rato ao implante de cimento de óxido de zinco e Eugenol (OZE), variando a proporção pó/líquido e o tempo de envelhecimento do Eugenol. *Rev. Odontol. UNESP, São Paulo*, 25(1):135-44, 1996.
- Da Silva, L. A. B.; Perassi, F. T.; Iro, I. Y.; Yamashita, J. C.; Bonifácio, K. C. & Tanomaru Filho, M. A presença de fungos nas infecções endodônticas. *UNIMEP*, 12(1-2):62-6, 2000.
- De Deus, Q. D. *Endodontia*. 5ª ed. Rio de Janeiro, Medsi, 2002. pp.208-11.
- Desai, M.; Gulabivala, K.; Ng, Y-L. & Spratt, D. Co-aggregation studies on bacteria isolated from root canal infections. *Int. Endod. J.*, 37:345-7, 2004.
- Estrela, C. *Metodologia Científica: Ciência, Ensino, Pesquisa*. São Paulo, Artes Médicas, 2005. pp.231-73.
- Guidugli-Neto, J. *Elementos de patologia geral*. São Paulo, Santos Editora, 1997.
- Junqueira, L. & Carneiro, J. *Histologia básica*. 7ª ed. Rio de Janeiro, Guanabara Koogan, 2003. pp.92-120.
- Kielbassa, A. M.; Uchtmann, H.; Wrbas, T. & Bitter, K. In vitro study assessing apical leakage of sealer-only backfills in root canals of primary teeth. *J. Dent.*, 35(7):607-13, 2007.
- Koulaouzidou, E. A.; Konstatinos, T. P.; Economides, N. A.; Panagiotis, B. & Kortisaris, A. H. Antiproliferative Effect of Mineral Trioxide Aggregate, Zinc Oxide-Eugenol Cement, and Glass Ionomer cement Against Three Fibroblastic Cell Lines. *J. Endod.*, 31(1):44-6, 2005.
- Man Chin, C. & Ferreira, E. I. O processo da latência no planejamento de fármacos. *Química Nova*, 22(1):75-84, 1999.
- Mandarim-de-Lacerda, C. A. Stereological tools in biomedical research. *An. Acad. Bras. Cienc.*, 75(4):469-86, 2003.
- Mattfeldt, T.; Krämer, K. L.; Zeitz, R. & Mall, G. Stereology of myocardial hypertrophy induced by physical exercise. *Virchows Arch A. Pathol. Anat. Histopathol.*, 409(4):473-84, 1986.
- Melker, K. B.; Vertucci, F. J.; Rojas, M. F.; Progulske-Fox, A. & Bélanger, M. Antimicrobial efficacy of medicated root canal filling materials. *J. Endod.*, 32(2):148-51, 2006.
- Minarelli, G. A. M. & Roslindo, B. E. Histologic analysis of the effects of an dentin adhesive prime bond 2.0 in pulp of rats. *Rev. Odontol. UNESP*, 32(2):105-11, 2003.
- Oliveira, M. R. B & Zamperini, C. A. Avaliação biológica em tecidos conjuntivos de ratos de materiais odontológicos utilizados para proteção pulpar. *Braz. Oral Res.*, 21:316, 2007.
- Oliveira, M. R. B.; Boldrini, S. C.; Comelli, R. C. & Lia, C. B. N. Compatibilidade Biológica de Materiais Odontológicos Fotopolimerizáveis e Ativados Quimicamente, Utilizados no Forramento de Cavidades (Baseline e Baseline Vlc). *Rev. Odontol. UNESP, São Paulo*, 26(2):255-64, 1997.
- Perdiza, W. *Tratamento conservador da polpa*. Bol. Da F.F. O, Rib. Preto, 1964. pp.137-140.
- Shay, D.E. Uso de antibióticos para conservação da vitalidade pulpar, *J. Den. Children*, 27:5-12, 1960.
- Shibl, A. M.; Pechère, J. C. & Ramadan, M. A. Postantibiotic effect and host-bacteria interactions. *J. Antimicrob. Chemother.*, 36(6):885-7, 1995.
- Souza, S. M. G.; Bramante, C. M. & Taga, E. M. Biocompatibilidade of EDTA, EGTA and citric acid. *Braz. Dent. J.*, 16:3-8, 2005.
- Sübay, R. K.; Cox, C. F.; Kaya, H.; Tarim, B.; Sübay, A. A. & Nayir, M. Human pulp reaction to dentine bonded amalgam restorations: a histologic study. *J. Dent.*, 28(5):327-32, 2000.
- Sunde, P. T.; Olsen, I.; Debelian, G. J. & Tronstad, L. Microbiota of periapical lesions refractory to endodontic therapy. *J. Endod.*, 28(4):304-10, 2002.
- Takahashi, K.; Dezan-Junior, E. & Cunha, R. F. Avaliação da Resposta Tecidual às pastas Guedes Pinto e de Hidróxido de Cálcio, Análise Edemogênica e ao Microscópio óptico em ratos. *Braz. oral res.*, 21:310, 2007.
- Tronstad, L.; Barnett, F. & Cervone, F. Periapical bacterial plaque in teeth refractory to endodontic

treatment. *Endod. Dent. Traumatol.*, 6(2):73-7, 1990.

Vigil, G. V.; Wayman, B. E.; Dazey, S. E.; Fowler, C. B. & Bradley, Jr. D.V. Identification and antibiotic sensitivity of bacteria isolated from periapical lesions. *J. Endod.*, 23(2):110-4, 1997.

Watts, A. & Paterson, R. C. Pulpal response to a zinc oxide-eugenol cement. *Int. Endod. J.*, 20(2):82-6, 1987.

Windley, W.; Teixeira, F.; Levin, L.; Sigurdsson, A. & Trope, M. Disinfection of immature teeth with a triple antibiotic paste. *J. Endod.*, 31(6):439-43, 2005.

Walther, L. F. *Odontologia e comunidade*. São Paulo, Artes médicas, 1965. pp6-11.

Correspondence to:

Elisabeth Cristina Gomes de Mattos
Rua Artista Bittencourt, n° 160 apto 203
Florianópolis
Zip Code:88020060
Santa Catarina, BRAZIL

Phone:554832242698

Email: elisabethgm@hotmail.com

Received: 22-02-2008

Accepted: 10-04-2008